



**PATIENT**      **PRESENTING CLINICAL SIGNS**

Wang Hughes      History: Came in for dental today has grade 2 heart murmur  
Abnormal PE/Chem/CBC/UA Results: Normal on PABW last week

**SPECIES**      **RADIOGRAPHIC STUDY OF THE THORAX**

Canine      A complete set of radiographs of the thorax is provided for review.

**BREED**      **RADIOGRAPHIC FINDINGS**

Chinese Crested      The surrounding bony structures are within normal limits.  
The extrathoracic soft tissues present homogeneous without abnormalities.

**SEX**      The heart is of normal size and shape, there is no evidence of cardiac chamber or vascular enlargement.  
The pulmonary vasculature is within normal limits.

Neutered Male      The cranial mediastinum presents the expected soft tissue opacity. The mediastinal width is less than twice the width of the vertebral column at the same level.

**AGE**      The trachea is normal in diameter and presents the anticipated course. The luminal outline of the trachea is smooth.  
10 Years      The bronchial tree presents with thin walls and tapers uniformly towards the periphery as expected. The lung parenchyma presents the expected architecture and opacity; the intrapulmonary vascular branching is seen up to the third order lung vessels.

**INTERPRETED BY**      The diaphragm is well delineated with even surface and the expected mild cranial bulging of the diaphragmatic cupola.

Sebastian Schaub,  
DVM Dr. med. vet.  
DipECVDI

**RADIOGRAPHIC DIAGNOSIS**

- Structural normal thorax, no evidence of cardiac enlargement

**HOSPITAL NAME**

Sylvan Lake VC

**INTERPRETATION OF THE FINDINGS & FURTHER RECOMMENDATIONS**

The current radiographic study of the thorax presents no abnormalities. A cardiac echo can be considered for further definition of cardiac chamber size and function.

**REFERRING VET**

Dr. Andrew Hodges

**The information and recommendations provided are based on the images presented by the referring veterinarian. No evaluation can be communicated regarding pathology that was not visible in the image/video clips provided.**

**INVOICE**

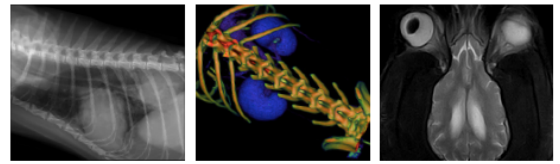
12988

Thank you for this referral. If the clinical or image interpretation does not parallel your findings or if I can be of any further assistance please contact me.

**Sebastian Schaub**, Sebastian Schaub, DVM, Dr. med. vet. DipECVDI  
sebast.schaub@gmail.com

**DATE**

9/8/21



**PATIENT**

Wang Hughes

**SPECIES**

Canine

**BREED**

Chinese Crested

**SEX**

Neutered Male

**AGE**

10 Years

**INTERPRETED BY**

Sebastian Schaub,  
DVM Dr. med. vet.  
DipECVDI

**HOSPITAL NAME**

Sylvan Lake VC

**REFERRING VET**

Dr. Andrew Hodges

**INVOICE**

12988

**DATE**

9/8/21