


PATIENT PRESENTING CLINICAL SIGNS

Sadie Siple
 History: Lameness LRL, semi chronic. R leg had MPL sx. No significant luxation of patella.
 Abnormal PE/Chem/CBC/UA Results:

SPECIES COMPUTED TOMOGRAPHIC STUDY OF THE RIGHT STIFLE JOINT

Canine A high resolution pre- and post-contrast CT study of the right stifle joint is provided for review.

COMPUTED TOMOGRAPHIC FINDINGS
BREED

Mix

The right stifle joint presents a moderate intracapsular soft tissue swelling, distorting the infrapatellar fat pad cranially and fascial plane caudally. Post contrast administration a moderate thickening of the synovial capsule is visible. A well defined nodular mineralization of the joint capsule is seen in the laterocaudal aspect. The periarticular bones of the right stifle joint present moderate osteophyte new bone formation and multiple degenerative osseous cyst like lesions are seen within the subchondral bone

SEX

Spayed Female

COMPUTED TOMOGRAPHIC DIAGNOSIS
AGE

2 Years

- Moderate articular swelling right stifle joint
- Moderate Synovialitis right stifle joint
- Moderate degenerative osteoarthritis right stifle joint
- Synovial osteochondromatosis right stifle joint

INTERPRETED BY

Sebastian Schaub,
 DVM Dr. med. vet.
 DipECVDDI

INTERPRETATION OF THE FINDINGS & FURTHER RECOMMENDATIONS

The findings are consistent with chronic degenerative osteoarthritis with concomitant joint effusion and synovialitis of the right stifle joint. The most-likely underlying cause is (partial) rupture of the cranial cruciate ligament with or without meniscal disease.

HOSPITAL NAME

Blairstown AH

A positive drawer sign or tibial compression test under general anesthesia can be used to confirm the diagnosis and surgical intervention – a correction osteotomy technique would be ideal – would be the preferred treatment option.

REFERRING VET

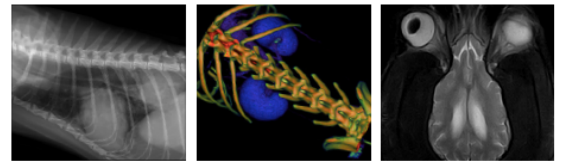
Dr. Leal

INVOICE

12992

DATE

9/8/21



PATIENT

Sadie Siple

SPECIES

Canine

BREED

Mix

SEX

Spayed Female

AGE

2 Years

INTERPRETED BY

Sebastian Schaub,
DVM Dr. med. vet.
DipECVCI

HOSPITAL NAME

Blirstown AH

REFERRING VET

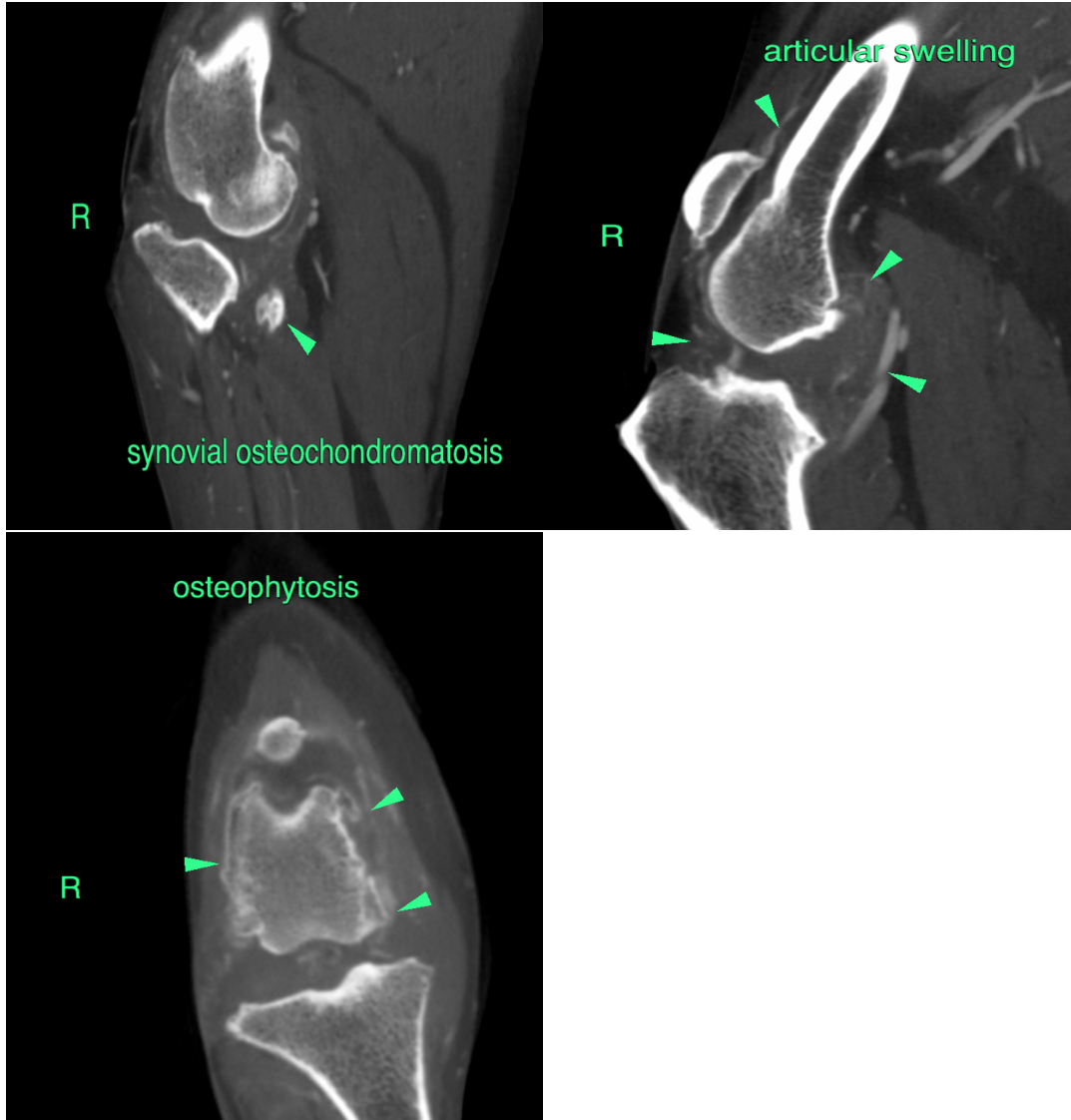
Dr. Leal

INVOICE

12992

DATE

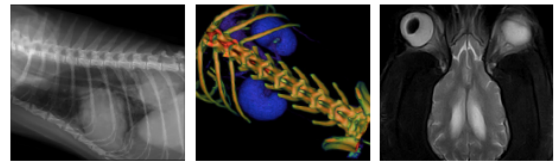
9/8/21



The information and recommendations provided are based on the images presented by the referring veterinarian. No evaluation can be communicated regarding pathology that was not visible in the image/video clips provided.

Thank you for this referral. If the clinical or image interpretation does not parallel your findings or if I can be of any further assistance please contact me.

Sebastian Schaub, Sebastian Schaub, DVM, Dr. med. vet. DipECVCI
sebast.schaub@gmail.com



PATIENT

Sadie Siple

SPECIES

Canine

BREED

Mix

SEX

Spayed Female

AGE

2 Years

INTERPRETED BY

Sebastian Schaub,
DVM Dr. med. vet.
DipECVDI

HOSPITAL NAME

Blairstown AH

REFERRING VET

Dr. Leal

INVOICE

12992

DATE

9/8/21