
PATIENT PRESENTING CLINICAL SIGNS

Nala Estrada History: History of suspected neoplasia of distal femur. Evaluate 3 view thx rads - Met check
 Abnormal PE/Chem/CBC/UA Results:

SPECIES RADIOGRAPHIC STUDY OF THE THORAX

Canine Radiographs of the thorax in three imaging planes are provided for review.

RADIOGRAPHIC FINDINGS
BREED

The surrounding bony structures are within normal limits.

Lab X

The extrathoracic soft tissues present homogeneous without abnormalities.

SEX

The heart is of normal size and shape, there is no evidence of cardiac chamber or vascular enlargement. The pulmonary vasculature is within normal limits.

Spayed Female

The cranial mediastinum presents the expected soft tissue opacity. The mediastinal width is less than twice the width of the vertebral column at the same level.

AGE

9 Years 10 Male

The trachea is normal in diameter and presents the anticipated course. The luminal outline of the trachea is smooth.

INTERPRETED BY

Sebastian Schaub,
 DVM Dr. med. vet.
 DipECVDI

The lung parenchyma presents a generalized increased radiopacity caused by an unstructured reticular lung pattern. Multiple variable sized, mild ill-defined soft tissue opaque nodular lesions are seen throughout the lung parenchyma, measuring up to 1.4 cm in size.

The diaphragm is well delineated with even surface and the expected mild cranial bulging of the diaphragmatic cupola.

RADIOGRAPHIC DIAGNOSIS
HOSPITAL NAME

Reid VH

- Structured nodular interstitial lung pattern

INTERPRETATION OF THE FINDINGS & FURTHER RECOMMENDATIONS
REFERRING VET

Diane Heider

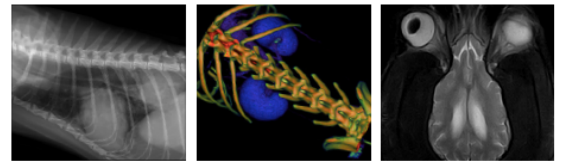
Given the history of potential primary osseous neoplasia, the pulmonary pattern is consistent with metastatic spread.

INVOICE

13001

DATE

9/8/21



PATIENT

Nala Estrada

SPECIES

Canine

BREED

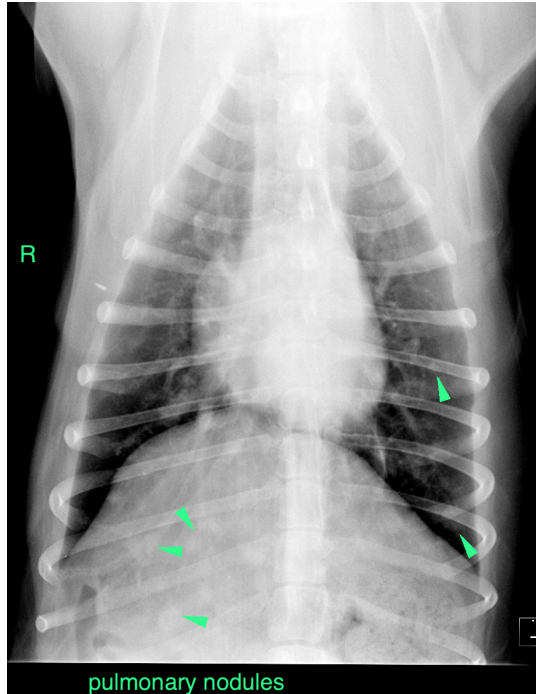
Lab X

SEX

Spayed Female

AGE

9 Years 10 Male



The information and recommendations provided are based on the images presented by the referring veterinarian. No evaluation can be communicated regarding pathology that was not visible in the image/video clips provided.

INTERPRETED BY

Sebastian Schaub,
DVM Dr. med. vet.
DipECVDI

Thank you for this referral. If the clinical or image interpretation does not parallel your findings or if I can be of any further assistance please contact me.

HOSPITAL NAME

Reid VH

Sebastian Schaub, Sebastian Schaub, DVM, Dr. med. vet. DipECVDI
sebast.schaub@gmail.com

REFERRING VET

Diane Heider

INVOICE

13001

DATE

9/8/21