SonoPath Teleradiology

EDUCATIONAL TELECONSULTATION SERVICES™

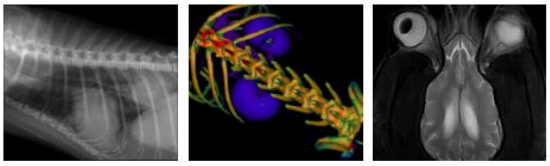

SonoPath.com
1-800-838-4268 info@sonopath.com

PATIENT

Tipper Rubin
Linestock Services

SPECIES

Canine

BREED

Cattle Dog Mix

SEX

Castrated Male

AGE

7 Years, 11 Months

INTERPRETED BY

Sebastian Schaub, DVM
Dr. med. vet. DipECVDI

HOSPITAL NAME

Catskill Veterinary Services, PLLC

REFERRING VET

Daniela Carbone, DVM

INVOICE

53969

DATE

9-7-22

PRESENTING CLINICAL SIGNS

The patient was presented for chronic vomiting (> 2 months) and progressive weight loss. The owner also noted that the patient has been very picky recently when eating.
Abnormal PE/Chem/CBC/UA Results: cbc - mild nonregenerative anemia Lactate increased 3.5 - with fluids

COMPUTED TOMOGRAPHY OF THE THORAX AND ABDOMEN

A high resolution pre- and post-contrast CT study of the abdomen and a plain CT study of the thorax are provided for review.

COMPUTED TOMOGRAPHIC FINDINGS

Thorax

The bony and surrounding soft tissue structures are within normal limits.

The sternal, cranial mediastinal and tracheobronchial lymph nodes are small elongated with a normal short-to-long-axis-ratio is < 0.5, the attenuation and contrast enhancement pattern is uniform and considered within normal limits.

The cardiovascular structures including the pulmonary vasculature are within normal limits.

The bronchial tree presents with regular branching and tapers uniformly towards the periphery as expected, the bronchial walls are thin and smooth. The bronchus-to-artery ratio is within normal limits.

The lung parenchyma presents the expected architecture and attenuation behavior with randomly distributed interspersed punctuate mineralization.

Small incidental gas pockets are seen within the esophageal lumen, there is no evidence of abnormal dilation.

Abdomen

Throughout the cranial abdomen, the peritoneal fat presents with multiple ill-defined soft tissue attenuating nodular lesions and accompanying mild fat-stranding.

Both kidneys present within normal limits for size, shape and organ architecture. After contrast administration a bilaterally symmetric and uniform nephro- and pyelogram is noted.

The adrenal glands are within normal limits for size, shape and organ architecture.

Both liver and spleen present with normal shape, even surface, uniformly attenuating parenchyma and homogeneous contrast enhancement, unremarkable.

The pancreas is evenly contoured, the pancreatic parenchyma is homogeneous and presents uniform contrast enhancement.

In the left cranial abdomen, a small intestinal segment, measuring approximately 7-8 cm in length, presents a significant circumferential mural thickening of the wall, measuring up to 16 mm in width. Post contrast administration, the respective thickened segment of the small intestinal loop has a irregular contrast enhancement pattern with loss of wall layering.

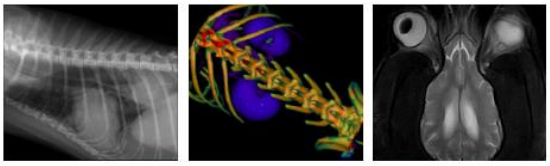

SonoPath.com
1-800-838-4268 info@sonopath.com

PATIENT

Tipper Rubin
Linestock Services

SPECIES

Canine

BREED

Cattle Dog Mix

SEX

Castrated Male

AGE

7 Years, 11 Months

INTERPRETED BY

Sebastian Schaub, DVM
Dr. med. vet. DipECVDI

HOSPITAL NAME

Catskill Veterinary Services, PLLC

REFERRING VET

Daniela Carbone, DVM

INVOICE

53969

DATE

9-7-22

The jejunal lymph nodes are prominent and mildly rounded; post contrast administration the jejunal lymph nodes have a heterogeneous contrast enhancement pattern.

An isolated, well-defined, mineralized body is seen in the tendon of the left iliopsoas muscle, medial to the minor trochanter of the left femur.

COMPUTED TOMOGRAPHIC DIAGNOSIS

- Segmental jejunal mural mass
- Lymphadenopathy jejunal lymph nodes
- Mild nodular pattern peritoneal fat cranial abdomen
- Metaplasia tendon left iliopsoas muscle
- Structural normal thorax, but pulmonary osteomas - no evidence of pulmonary metastatic disease

INTERPRETATION OF THE FINDINGS & FURTHER RECOMMENDATIONS

There is a segmental mural small intestinal mass, compatible with primary jejunal neoplasia. Differentials include adenocarcinoma, sarcoma, lymphosarcoma,, gastrointestinal stroma cell tumor, other. The odds for metastatic spread to the jejunal lymph nodes and the peritoneum are considered high – the latter might increase the odds for carcinomatosis.

Complete surgical excision of the respective small intestinal loop appears feasible, but due to the suspected metastatic disease the prognosis is guarded; discussing the chances of adjuvant chemotherapy with oncologist appears beneficial.

SonoPath Teleradiology

EDUCATIONAL TELECONSULTATION SERVICES™

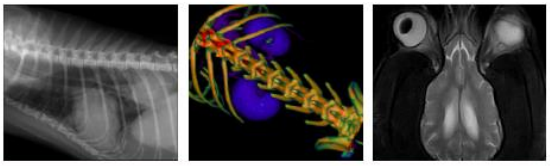

SonoPath.com
1-800-838-4268 info@sonopath.com

PATIENT

Tipper Rubin
Linestock Services

SPECIES

Canine

BREED

Cattle Dog Mix

SEX

Castrated Male

AGE

7 Years, 11 Months

INTERPRETED BY

Sebastian Schaub, DVM
Dr. med. vet. DipECVDI

HOSPITAL NAME

Catskill Veterinary Services, PLLC

REFERRING VET

Daniela Carbone, DVM

INVOICE

53969

DATE

9-7-22

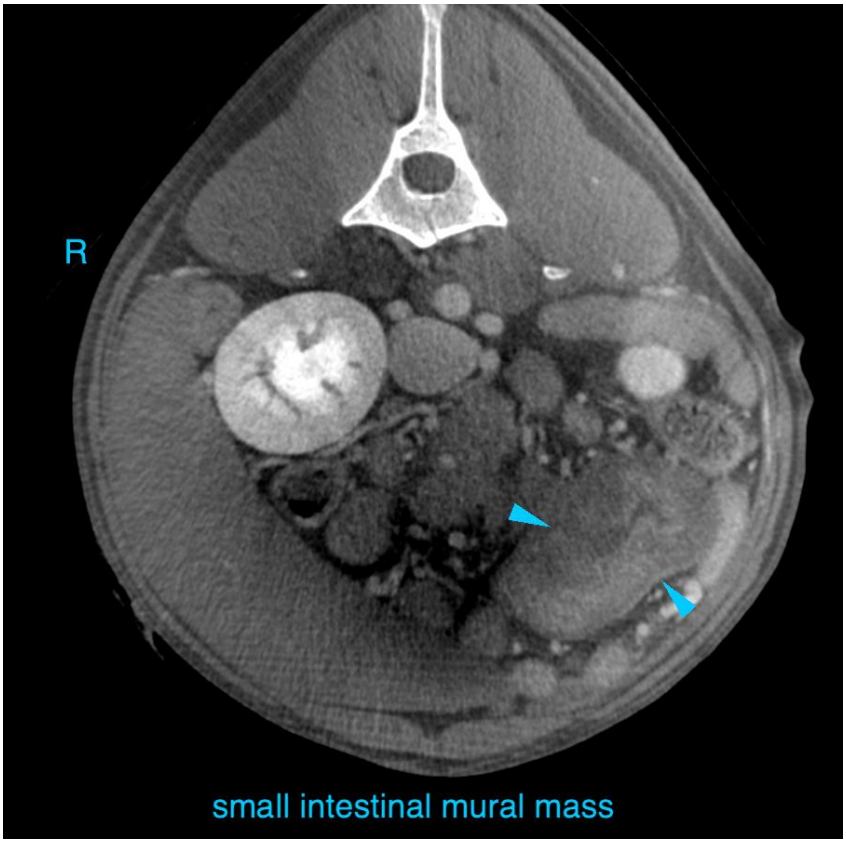

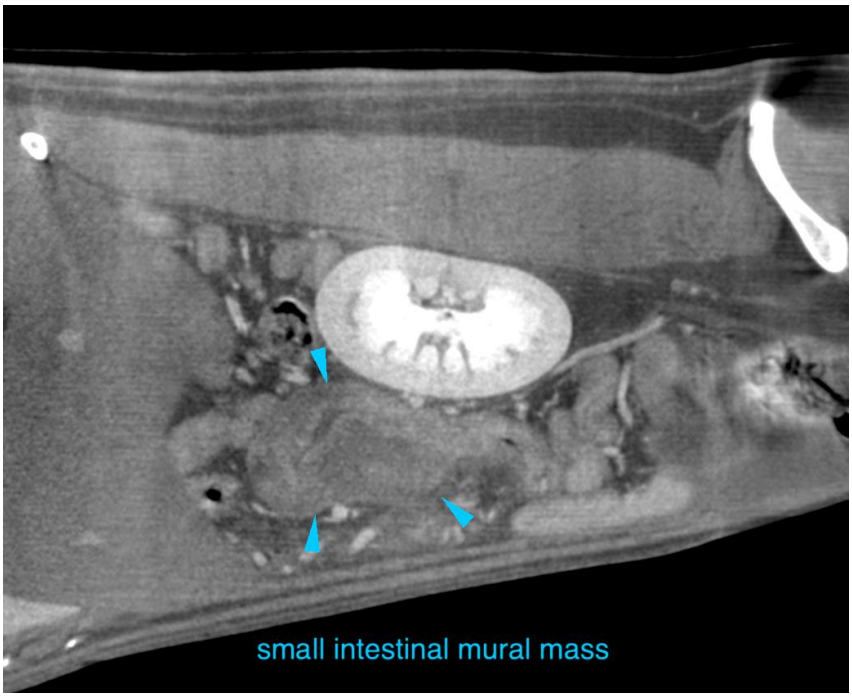

SonoPath Teleradiology

EDUCATIONAL TELECONSULTATION SERVICES™

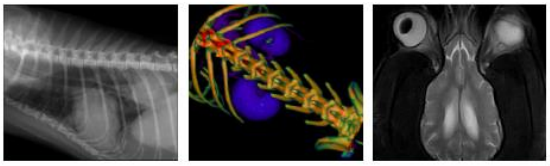

SonoPath.com
1-800-838-4268 info@sonopath.com

PATIENT

Tipper Rubin
Linestock Services

SPECIES

Canine

BREED

Cattle Dog Mix

SEX

Castrated Male

AGE

7 Years, 11 Months

INTERPRETED BY

Sebastian Schaub, DVM
Dr. med. vet. DipECVDI

HOSPITAL NAME

Catskill Veterinary Services, PLLC

REFERRING VET

Daniela Carbone, DVM

INVOICE

53969

DATE

9-7-22

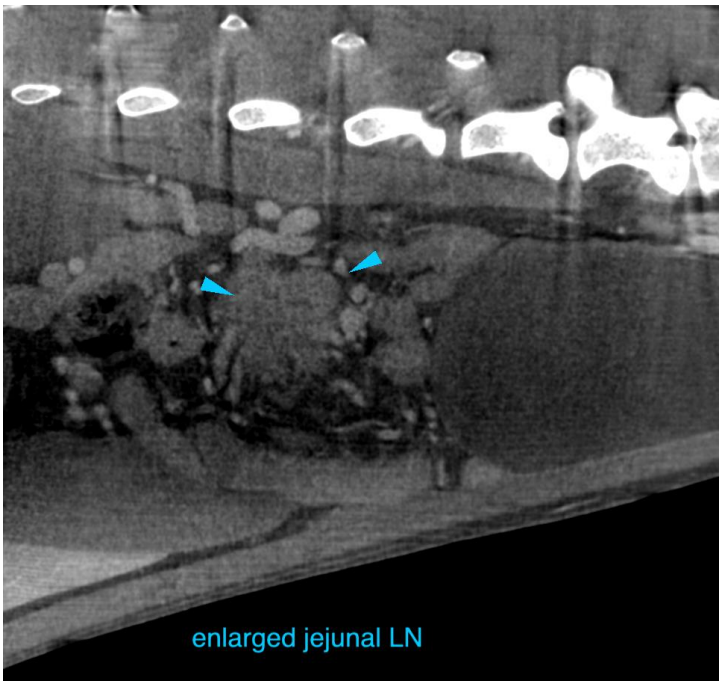

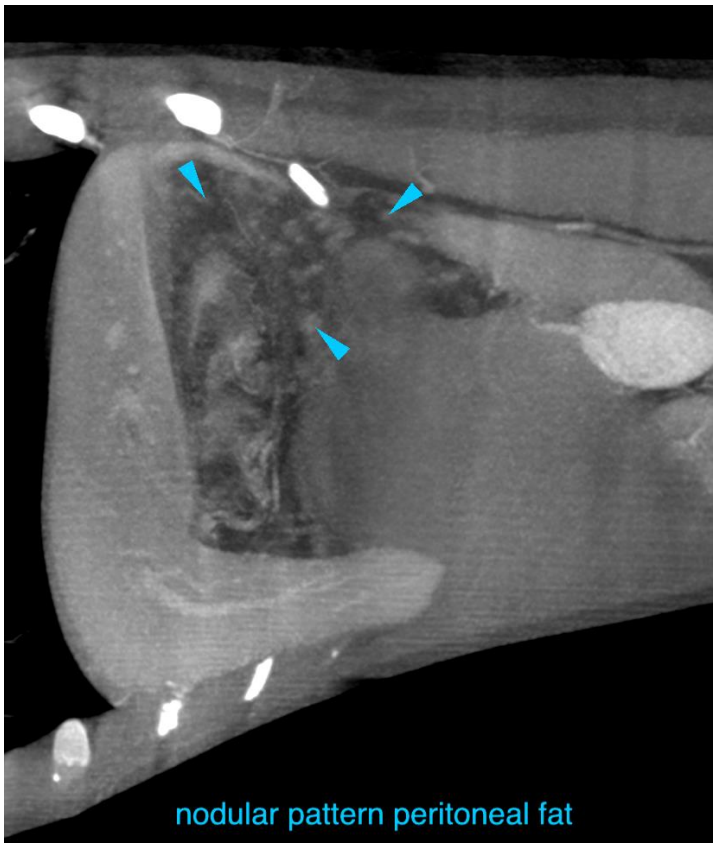

SonoPath Teleradiology

EDUCATIONAL TELECONSULTATION SERVICES™

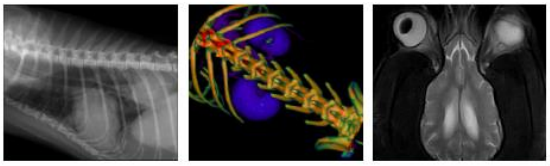

SonoPath.com
1-800-838-4268 info@sonopath.com

PATIENT

Tipper Rubin
Linestock Services

SPECIES

Canine

BREED

Cattle Dog Mix

SEX

Castrated Male

AGE

7 Years, 11 Months

INTERPRETED BY

Sebastian Schaub, DVM
Dr. med. vet. DipECVDI

HOSPITAL NAME

Catskill Veterinary Services, PLLC

REFERRING VET

Daniela Carbone, DVM

INVOICE

53969

DATE

9-7-22

The information and recommendations provided are based on the images presented by the referring veterinarian/sonographer. No evaluation can be communicated regarding pathology that was not visible in the image/video clips provided.

Thank you for this referral. If the clinical or image interpretation does not parallel your findings or if I can be of any further assistance please contact me.

Sebastian Schaub, Sebastian Schaub, DVM, Dr. med. vet. DipECVDI
sebast.schaub@gmail.com