



PATIENT PRESENTING CLINICAL SIGNS

Nala Kopelman
 Losing weight and decreased appetite
 Abnormal PE/Chem/CBC/UA Results: Hydration: Appropriately hydrated Mentation: BAR
 EENT: No nasal discharge; nuclear sclerosis OU; clean no debris AU; No cough on tracheal palpation. Oral Cavity: mild dental tartar present Lymph Nodes: Symmetrical, no changes in size, shape, consistency, except R popliteal seemingly slightly larger than L Skin: Good hair coat, no signs of ectoparasites. CV/Respiratory: No murmur or crackles/wheezing auscultated. Synchronous pulses, normal rate. Normal bronchovesicular sounds. Abd/GI:caudal abdominal pain Uro/Perineum: N Musculoskeletal: Ambulatory x4. Stilted gait in HL. Difficulty standing up. BCS 4/9 Neurological: Appropriate

SPECIES

Canine

BREED

Mixed

RADIOGRAPHIC STUDY OF THE THORAX

Radiographs of the thorax in two imaging planes are provided for review.

SEX

SF

RADIOGRAPHIC FINDINGS

Multifocal mild spondylosis formation is seen along the cranial thoracic spine.

The extrathoracic soft tissues present homogeneous without abnormalities.

AGE

12 Years

The heart is of normal size and shape, there is no evidence of cardiac chamber or vascular enlargement. The pulmonary vasculature is within normal limits.

The cranial mediastinum presents the expected soft tissue opacity. The mediastinal width is less than twice the width of the vertebral column at the same level.

The trachea is normal in diameter and presents the anticipated course. The luminal outline of the trachea is smooth.

Multifocal throughout the lung parenchyma, well-defined soft tissue opaque nodules are visible, measuring up to 13 mm in size.

The diaphragm is well delineated with even surface and the expected mild cranial bulging of the diaphragmatic cupola.

RADIOGRAPHIC DIAGNOSIS

- Structured nodular interstitial lung pattern
- Spondylosis deformans

INTERPRETATION OF THE FINDINGS & FURTHER RECOMMENDATIONS

The structured nodular interstitial lung pattern is highly suggestive for pulmonary metastatic disease. Theoretically granulomatous lung disease is a consideration, but the odds are considered low. A primary neoplasia is not appreciated, recommend complementing workup by an abdominal ultrasound to screen for primary neoplastic disease.

DATE

9-7-22

INTERPRETED BY

Sebastian Schaub, DVM
 Dr. med. vet. DipECVDI

HOSPITAL NAME

DPC Veterinary Hospital

REFERRING VET

Dr. White

INVOICE

54002



PATIENT

Nala Kopelman

SPECIES

Canine

BREED

Mixed

SEX

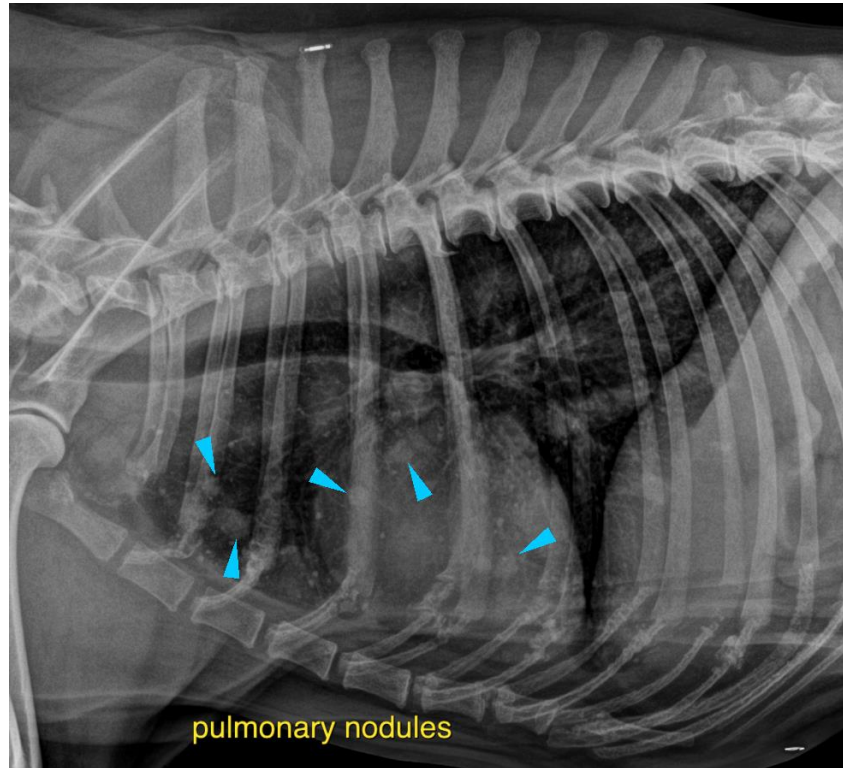
SF

AGE

12 Years

INTERPRETED BY

Sebastian Schaub, DVM
Dr. med. vet. DipECVDI



HOSPITAL NAME

DPC Veterinary
Hospital

REFERRING VET

Dr. White

INVOICE

54002

DATE

9-7-22

The information and recommendations provided are based on the images presented by the referring veterinarian/sonographer. No evaluation can be communicated regarding pathology that was not visible in the image/video clips provided.

Thank you for this referral. If the clinical or image interpretation does not parallel your findings or if I can be of any further assistance please contact me.

Sebastian Schaub, Sebastian Schaub, DVM, Dr. med. vet. DipECVDI
sebast.schaub@gmail.com