



PATIENT

PRESENTING CLINICAL SIGNS

Daisy Boo Boo Homel

History of hunched posture and stiff-legged hind limb gait in episodes. On exam 8/16/22 lumbosacral spinal pain was elicited and pt was resistant to extension of left hip. On exam today pt did not demonstrate spinal pain, resisted bilateral hip extension, and was flinching on palpation off cranial abdomen.

SPECIES

Canine

RADIOGRAPHIC STUDY OF THE ABDOMEN & LUMBAR SPINE

Radiographs of the abdomen in two orthogonal imaging planes are provided for review.

BREED

Terrier Mix

RADIOGRAPHIC FINDINGS

The intervertebral disc space T12/T13 is moderately narrowed and the respective vertebral endplates present

SEX

Female Spayed

No abnormalities of the extraabdominal soft tissues are noted. The abdominal wall is smooth and thin.

The serosal detail is maintained throughout the peritoneal and retroperitoneal space.

AGE

11 Years

The hepatic volume is mild to moderately increased, the liver is protruding mildly caudally beyond the costal arch and the caudoventral margins are rounded.

The splenic head is in the anticipated position and within normal limits for size and opacity. The splenic body and tail are considered normal for position, size, shape and opacity.

INTERPRETED BY

Sebastian Schaub, DVM
Dr. med. vet. DipECVDI

Both kidneys are seen and present with normal size, shape, delineation and opacity. The urinary bladder is in its anticipated position. No radiopaque calculi are noted throughout the upper and lower urinary tract.

The stomach is in its anticipated position and presents normal content.

HOSPITAL NAME

Northshore
Veterinary Hospital

The small intestinal loops are of even diameter and non-dilated, a small amount of gas is seen within the small intestinal loops and considered within normal limits.

The colon is seen in the expected position and presents with appropriate content.

RADIOGRAPHIC DIAGNOSIS

REFERRING VET

Sophie Lee, DVM

- Discopathy T12/T13
- Mild hepatomegaly

INTERPRETATION OF THE FINDINGS & FURTHER RECOMMENDATIONS

INVOICE

54005

The narrowed intervertebral disc space T12/T13 indicates discopathy that might or might not be associated with compressive myelopathy.

Potentials for the hepatomegaly include metabolic hepatic disease/steroid induced hepatopathy, hepatitis or neoplastic infiltration. Ultrasound including FNA sampling can be used as minimally advanced diagnostic tests.

DATE

9-7-22



PATIENT

Daisy Boo Boo Homel

SPECIES

Canine

BREED

Terrier Mix

SEX

Female Spayed

AGE

11 Years

INTERPRETED BY

Sebastian Schaub, DVM
Dr. med. vet. DipECVDI

HOSPITAL NAME

Northshore
Veterinary Hospital

REFERRING VET

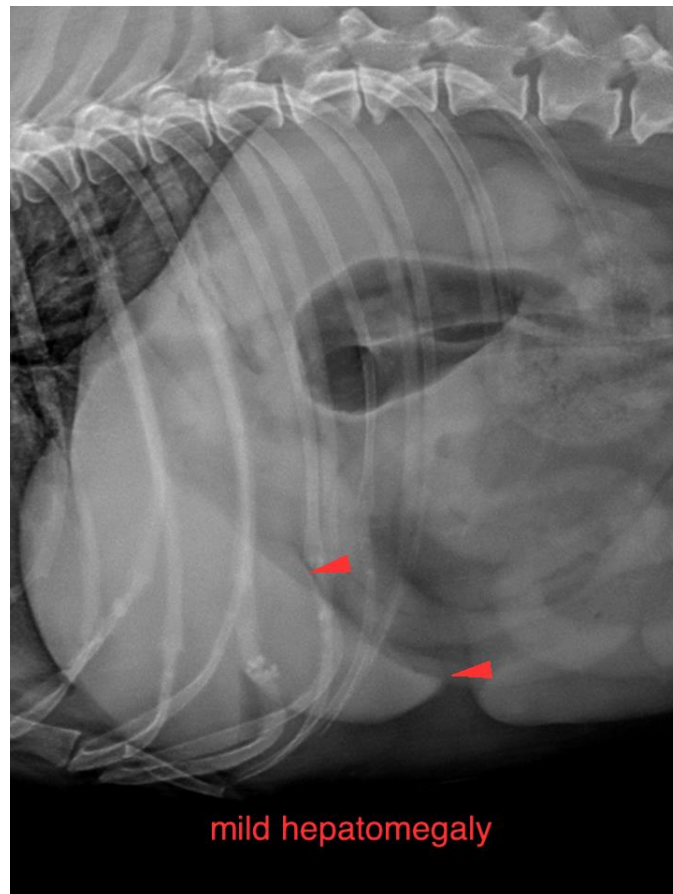
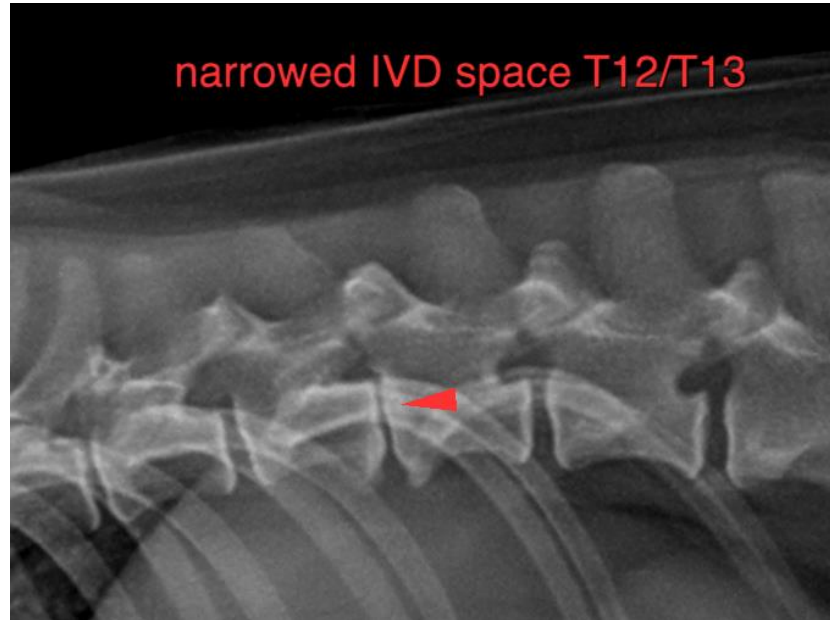
Sophie Lee, DVM

INVOICE

54005

DATE

9-7-22





PATIENT

Daisy Boo Boo Homel

SPECIES

Canine

The information and recommendations provided are based on the images presented by the referring veterinarian/sonographer. No evaluation can be communicated regarding pathology that was not visible in the image/video clips provided.

BREED

Terrier Mix

Thank you for this referral. If the clinical or image interpretation does not parallel your findings or if I can be of any further assistance please contact me.

Sebastian Schaub, Sebastian Schaub, DVM, Dr. med. vet. DipECVDI
sebast.schaub@gmail.com

SEX

Female Spayed

AGE

11 Years

INTERPRETED BY

Sebastian Schaub, DVM
Dr. med. vet. DipECVDI

HOSPITAL NAME

Northshore
Veterinary Hospital

REFERRING VET

Sophie Lee, DVM

INVOICE

54005

DATE

9-7-22