



PATIENT

Tasha Quinones

PRESENTING CLINICAL SIGNS

Patient came for evaluation after two episodes of convulsion over night. No previous history of convulsions. Only current medication trazodone given as needed last night after second episode. No vomiting or diarrhea.

SPECIES

Canine

Abnormal PE/Chem/CBC/UA Results: CBC --- unremarkable CHEM --- unremarkable

COMPUTED TOMOGRAPHY OF THE SKULL

A high resolution pre- and post-contrast CT study of the is provided for review.

BREED

Basset Hound

COMPUTED TOMOGRAPHIC FINDINGS

A supernumerary tooth element 105&205 is seen.

SEX

SF

The nasal cavity presents the expected aerated spaces between thin & even conchae and turbinates with smooth mucosal lining.

Both temporomandibular joints present congruent joint spaces with even subchondral bone surfaces and are considered within normal limits.

AGE

17 Years

Both tympanic bullae are aerated, the mucosal lining is not seen, the bony wall is smooth and thin. The external ear canals are within normal limits.

INTERPRETED BY

Sebastian Schaub, DVM
Dr. med. vet. DipECVDI

The brain presents no deviation from normal anatomy and symmetry. The brain parenchyma is homogeneous and within normal limits for attenuation and distribution of contrast enhancement. The ventricular system is non-dilated and symmetric.

HOSPITAL NAME

Veterinary Image Center

The submandibular and medial retropharyngeal lymph nodes are small and elongated with a normal short-to-long-axis-ratio is < 0.5, the attenuation and contrast enhancement pattern is uniform.

Originating from the right thyroid gland, a well-defined, ovoid shaped, uniform soft tissue attenuating and heterogeneous moderate to marked contrast enhancing nodular lesion is visible, measuring 22 x 16 x 31 mm in size.

REFERRING VET

Dr. J. Walker, DVM

COMPUTED TOMOGRAPHIC DIAGNOSIS

- Right thyroid mass
- Supernumerary triadan 105&205
- Structural normal brain

INVOICE

47367

INTERPRETATION OF THE FINDINGS & FURTHER RECOMMENDATIONS

In the present study of the brain there is no evidence of macromorphological disease. However, a negative CT study does not rule out ischemic insult.

DATE

9-7-21

If not yet done so the workup should be complemented by examination of CSF and complete bloodwork to screen for brain disease that is not necessarily associated with structural changes of the brain parenchyma and rule out hepatoencephalopathy and other systemic illness. In case of



PATIENT

Tasha Quinones

the strong clinical suspicion of structural intraparenchymal changes an MRI may be considered.

The right thyroid mass is suggestive for non-functional thyroid nodular hyperplasia or neoplasia such as adenoma or carcinoma. There is no evidence of macroscopic vascular invasion.

SPECIES

Canine

BREED

Basset Hound

SEX

SF

AGE

17 Years

INTERPRETED BY

Sebastian Schaub, DVM
Dr. med. vet. DipECVDI

HOSPITAL NAME

Veterinary Image
Center

REFERRING VET

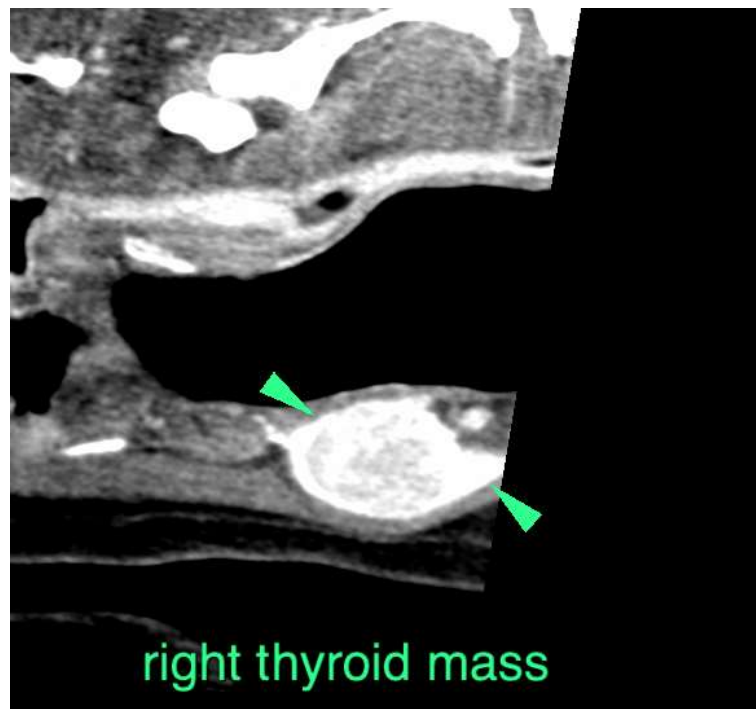
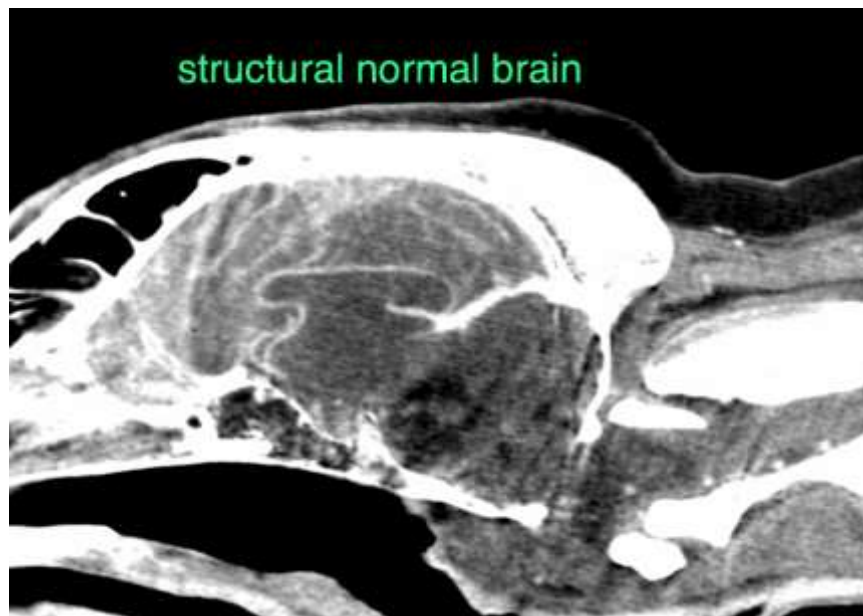
Dr. J. Walker, DVM

INVOICE

47367

DATE

9-7-21





PATIENT

Tasha Quinones

SPECIES

Canine

The information and recommendations provided are based on the images presented by the referring veterinarian. No evaluation can be communicated regarding pathology that was not visible in the image/video clips provided.

BREED

Basset Hound

Thank you for this referral. If the clinical or image interpretation does not parallel your findings or if I can be of any further assistance please contact me.

Sebastian Schaub, Sebastian Schaub, DVM, Dr. med. vet. DipECVDI
sebast.schaub@gmail.com

SEX

SF

AGE

17 Years

INTERPRETED BY

Sebastian Schaub, DVM
Dr. med. vet. DipECVDI

HOSPITAL NAME

Veterinary Image
Center

REFERRING VET

Dr. J. Walker, DVM

INVOICE

47367

DATE

9-7-21