



PATIENT PRESENTING CLINICAL SIGNS

Onyx Lancey Presented to ophthalmologist due to Orbital/third eyelid adenocarcinoma (Prev. CT and biopsy 2019). Multiple surgeries afterwards. No radiation. Would like to know invasion/if bone involvement prior to enucleation

SPECIES Abnormal PE/Chem/CBC/UA Results: Ventral orbital mass causing exophthalmia and dorsal deviation of the globe.

Canine

COMPUTED TOMOGRAPHY OF THE SKULL

BREED

A high resolution pre- and post-contrast CT study of the skull is provided for review.

Labrador Retriever

COMPUTED TOMOGRAPHIC FINDINGS

The pictured parts of the dentition are complete and unremarkable in all jaw quadrants.

SEX

Male Neutered

In the left orbit, a uniform soft tissue attenuating and heterogeneous contrast enhancing mass is visible displacing the left ocular bulb dorsally and rostrally. The left sided orbital mass is extending caudally up to the cranial margin of the ramus of the left mandible and rostrally into the caudal segment of the left infraorbital canal, presenting a moderate increased diameter and beyond the rostroventral osseous margin of the left orbit. The rostral margin of the left ramus of the mandible presents mild irregular margins. The left zygomatic arch presents moderate pressure erosion. The left orbital mass is measuring approximately 3.3 x 5.8 x 6.0 cm in size.

AGE

9 Years

INTERPRETED BY

Sebastian Schaub, DVM
Dr. med. vet. DipECVDI

The nasal cavity presents the expected aerated spaces between thin & even conchae and turbinates with smooth mucosal lining.

Both temporomandibular joints present congruent joint spaces with even subchondral bone surfaces and are considered within normal limits.

HOSPITAL NAME

Mobile Pet Imaging

Both tympanic bullae are aerated, the mucosal lining is not seen, the bony wall is smooth and thin. The external ear canals are within normal limits.

The brain presents no deviation from normal anatomy and symmetry. The brain parenchyma is homogeneous and within normal limits for attenuation and distribution of contrast enhancement. The ventricular system is non-dilated and symmetric.

REFERRING VET

Meaux

The submandibular and medial retropharyngeal lymph nodes are small and elongated with a normal short-to-long-axis-ratio is < 0.5, the attenuation and contrast enhancement pattern is uniform.

INVOICE

47368

COMPUTED TOMOGRAPHIC DIAGNOSIS

DATE

9-7-21

- Left sided orbital mass with pressure erosion and polyostotic semi-aggressive osteolytic lesions of the left zygomatic bone, left ramus of the mandible and extension into the left infraorbital canal.
- Evidence of osteolysis rostral margin left ramus of mandible
- Secondary left sided exophthalmos



PATIENT

Onyx Lancey

SPECIES

Canine

BREED

Labrador Retriever

SEX

Male Neutered

AGE

9 Years

INTERPRETED BY

Sebastian Schaub, DVM
Dr. med. vet. DipECVDI

HOSPITAL NAME

Mobile Pet Imaging

REFERRING VET

Meaux

INVOICE

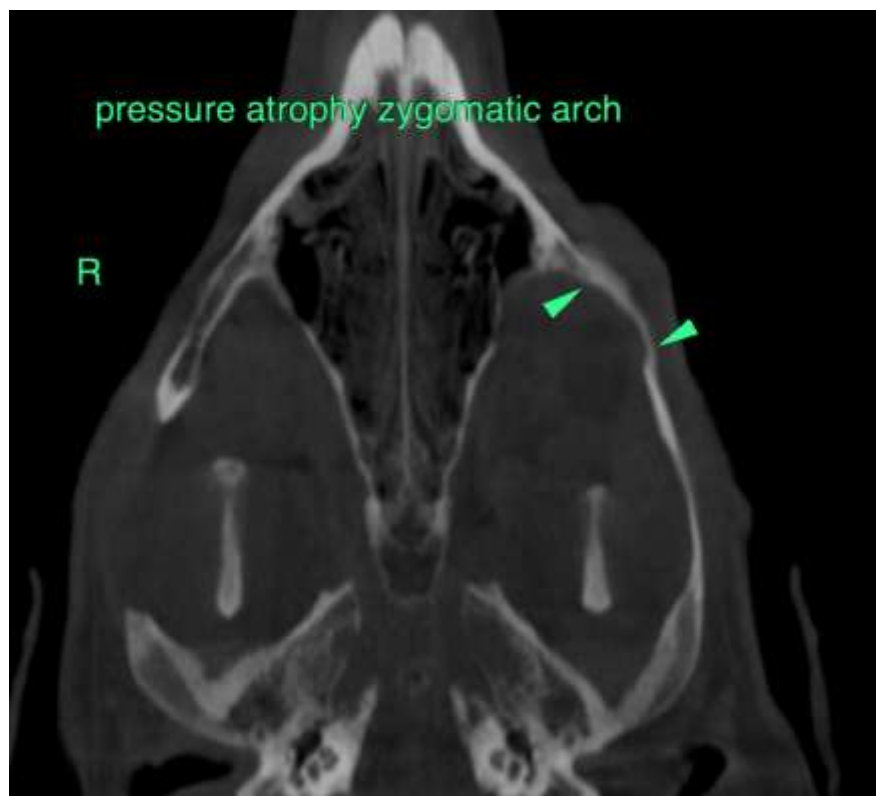47368

DATE

9-7-21

INTERPRETATION OF THE FINDINGS & FURTHER RECOMMENDATIONS

The left orbital mass is fitting the history of adenocarcinoma with secondary pressure erosion of the associated osseous structures and osteolysis of the associated osseous local osseous structures. Surgical excision of the mass by exenteration of the right orbit can be tried, but due to the extent of the mass recurrence is considered likely and the chances of adjuvant radiation therapy should be discussed with oncologist as well. Surgery may warrant resection of major parts of the left zygomatic arch as well.





PATIENT

Onyx Lancey

SPECIES

Canine

BREED

Labrador Retriever

SEX

Male Neutered

AGE

9 Years

INTERPRETED BY

Sebastian Schaub, DVM
Dr. med. vet. DipECVDI

HOSPITAL NAME

Mobile Pet Imaging

REFERRING VET

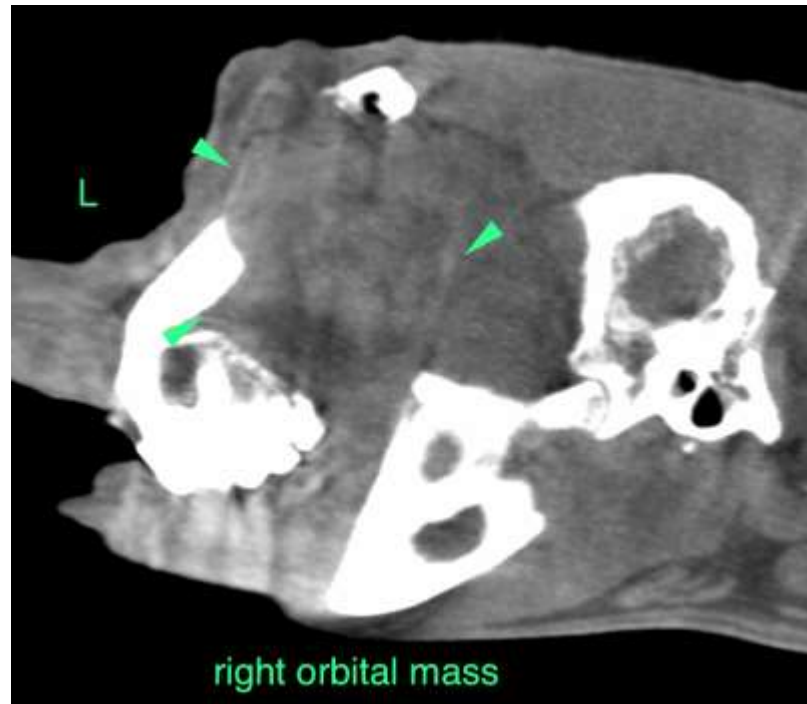Meaux

INVOICE

47368

DATE

9-7-21





PATIENT

Onyx Lancey

SPECIES

Canine

BREED

Labrador Retriever

SEX

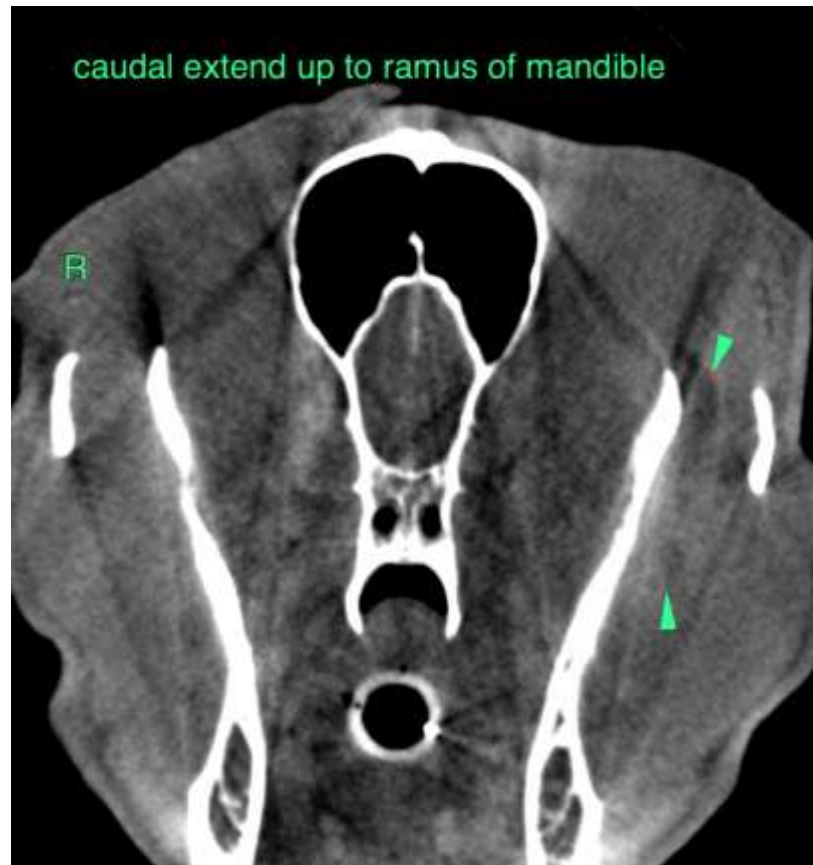
Male Neutered

AGE

9 Years

INTERPRETED BY

Sebastian Schaub, DVM
Dr. med. vet. DipECVDI



HOSPITAL NAME

Mobile Pet Imaging

REFERRING VET

Meaux

INVOICE

47368

DATE

9-7-21

The information and recommendations provided are based on the images presented by the referring veterinarian. No evaluation can be communicated regarding pathology that was not visible in the image/video clips provided.

Thank you for this referral. If the clinical or image interpretation does not parallel your findings or if I can be of any further assistance please contact me.

Sebastian Schaub, Sebastian Schaub, DVM, Dr. med. vet. DipECVDI
sebast.schaub@gmail.com