



**PATIENT PRESENTING CLINICAL SIGNS**

Oscar Curry INTERMITTENT NON WEIGHT BEARING LAMENESS LEFT HIND; LR DIGIT 4 HAS DORSALLY POINTING NAIL; DIGIT 4 IS THICKENED WITH NO PALPABLE MASS; SUSPECTED THICKENING ASSOCIATED WITH PAW PAD

**SPECIES COMPUTED TOMOGRAPHY OF THE HIND LIMBS**

Canine A high resolution pre- and post-contrast CT study of the left hind paw is provided for review.

**COMPUTED TOMOGRAPHIC FINDINGS**

**BREED** The fourth digit of the left hind paw presents a mild circumferential soft tissue swelling. The osseous structures of the right hind paw present no abnormalities.

Miniature Poodle

**COMPUTED TOMOGRAPHIC DIAGNOSIS**

- SEX** • Mild soft tissue swelling fourth digit left hind paw

MN

**INTERPRETATION OF THE FINDINGS & FURTHER RECOMMENDATIONS**

**AGE**

There is a soft tissue swelling of the fourth digit of the left hind paw, this is a non-specific finding and trauma, inflammation or due to the lack of osseous changes less likely neoplasia are considerations. Check if pain can be elicited by palpation of the fourth digit.

13 Years

**INTERPRETED BY**

Sebastian Schaub, DVM  
Dr. med. vet. DipECVDI

**HOSPITAL NAME**

Mobile Pet Imaging  
CFL

**REFERRING VET**

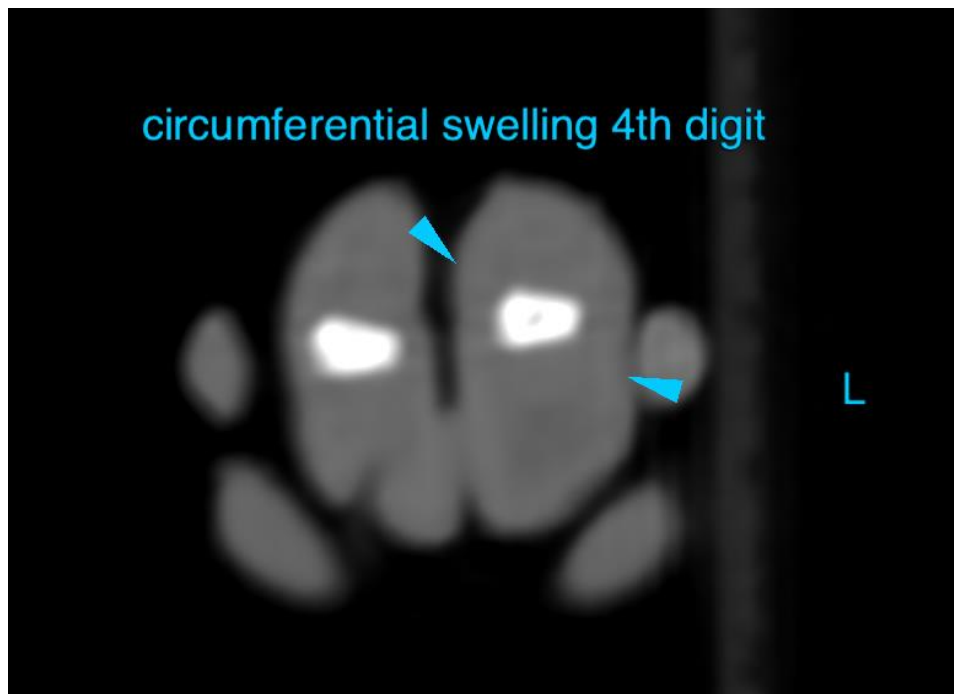
Borecky

**INVOICE**

53966

**DATE**

9-6-22





**PATIENT**

Oscar Curry

The information and recommendations provided are based on the images presented by the referring veterinarian/sonographer. No evaluation can be communicated regarding pathology that was not visible in the image/video clips provided.

**SPECIES**

Canine

Thank you for this referral. If the clinical or image interpretation does not parallel your findings or if I can be of any further assistance please contact me.

**BREED**

Miniature Poodle

**Sebastian Schaub**, Sebastian Schaub, DVM, Dr. med. vet. DipECVDI  
sebast.schaub@gmail.com

**SEX**

MN

**AGE**

13 Years

**INTERPRETED BY**

Sebastian Schaub, DVM  
Dr. med. vet. DipECVDI

**HOSPITAL NAME**

Mobile Pet Imaging  
CFL

**REFERRING VET**

Borecky

**INVOICE**

53966

**DATE**

9-6-22