



PATIENT PRESENTING CLINICAL SIGNS

Kiley Farrelly mass on kidney

COMPUTED TOMOGRAPHY OF THE THORAX AND ABDOMEN

SPECIES A high resolution post contrast CT study of the thorax and abdomen is provided for review.

Canine **COMPUTED TOMOGRAPHIC FINDINGS**

Thorax

BREED The intervertebral disc C6/C7 is mild to moderately protruding into the vertebral canal, distorting the ventral epidural space. The vertebral endplates C6/C7 present mild spondylosis formation.

Mix Breed

In the shoulder region, bilaterally, lipomas are appreciated.

SEX The sternal, cranial mediastinal and tracheobronchial lymph nodes are small elongated with a normal short-to-long-axis-ratio is < 0.5, the attenuation and contrast enhancement pattern is uniform and considered within normal limits.

FS

The cardiovascular structures including the pulmonary vasculature are within normal limits.

AGE

13 Years

The bronchial tree presents with regular branching and tapers uniformly towards the periphery as expected, the bronchial walls are thin and smooth. The bronchus-to-artery ratio is within normal limits.

INTERPRETED BY

Sebastian Schaub, DVM
Dr. med. vet. DipECVDI

The lung parenchyma presents the expected architecture and attenuation behavior.

Small incidental gas pockets are seen within the esophageal lumen, there is no evidence of abnormal dilation.

HOSPITAL NAME Abdomen

Animal Surgical Center

Image contrast is limited by multiple streak artefacts emanating from the gastrointestinal tract.

The serosal fat presents normal attenuation behavior. There is no evidence of peritoneal effusion or peritonitis.

REFERRING VET

North Shore Vet Hospital

Both kidneys present within normal limits for size, shape and organ architecture. After contrast administration a bilaterally symmetric and uniform nephro- and pyelogram is noted. The cranial segment of the urethra is dilated by post contrast hypoattenuating material; measuring up to 11 mm in diameter.

The adrenal glands are within normal limits for size, shape and organ architecture.

INVOICE

53947

Both liver and spleen present with normal shape, even surface, uniformly attenuating parenchyma and homogeneous contrast enhancement, unremarkable.

DATE

9-6-22

In the cranioventral abdomen, caudal to the pylorus of the stomach, dorsal to the caudal extremity of the spleen, a well-defined spherical mass presenting a heterogeneous attenuation pattern - appears to be fat attenuating in the center -is appreciated, measuring 4.8 x 6.0 x 5.9 cm in size. The mass is in contact with the caudal extremity of the spleen, the small intestinal loops are centrifugally displaced.

**PATIENT**

Kiley Farrelly

The lumbosacral intervertebral disc is moderately protruding into the vertebral canal, occupying approximately 50% of the cross-sectional area of the vertebral canal at the same level. The vertebral endplates L1/L2 and L2/L3 present moderate spondylosis formation. Both coxofemoral joints present moderate to marked osteophyte new bone formation. The acetabular groove bilaterally is shallow, and the center of the femoral heads is lateral to the dorsal acetabular rim.

SPECIES

Canine

COMPUTED TOMOGRAPHIC DIAGNOSIS**BREED**

Mix Breed

- Right cranioventral abdominal soft tissue mass
- Possible intraluminal urethral mass
- Intervertebral disc protrusion C6/C7 and L7/S1 with possible dynamic myelocompression
- No evidence of pulmonary metastatic disease
- Degenerative osteoarthritis coxofemoral joints bilaterally, due to hip dysplasia
- Lipomas shoulder region bilaterally
- Spondylosis deformans

SEX

FS

INTERPRETATION OF THE FINDINGS & FURTHER RECOMMENDATIONS

There is a cranioventral abdominal mass, an organ of origin cannot be specified, the mass appears to present a fat-attenuating center. As the mass is in contact with the caudal extremity of the spleen, a pedunculated splenic mass (e.g. myelolipoma, hematoma, nodular hyperplasia), peritoneal mass (e.g. lipoma with necrosis, peritoneal myelolipoma, cystadenoma), lymphadenopathy. Overall, I consider the odds for benign lesion high. Complete surgical excision of the mass appears feasible. No abnormalities of the kidneys are appreciated – although small lesions might be missed due to image artifacts.

AGE

13 Years

The urethral dilation is concerning for intraluminal mural mass – such as transitional cell carcinoma – or hematoma within the urethra. Either cystoscopy including biopsy or ultrasound guided suction biopsy of the urethral lesion can be used as advanced diagnostic tool.

INTERPRETED BYSebastian Schaub, DVM
Dr. med. vet. DipECVDI**HOSPITAL NAME**Animal Surgical
Center**REFERRING VET**North Shore Vet
Hospital**INVOICE**

53947

DATE

9-6-22



PATIENT

Kiley Farrelly

SPECIES

Canine

BREED

Mix Breed

SEX

FS

AGE

13 Years

INTERPRETED BY

Sebastian Schaub, DVM
Dr. med. vet. DipECVDI

HOSPITAL NAME

Animal Surgical
Center

REFERRING VET

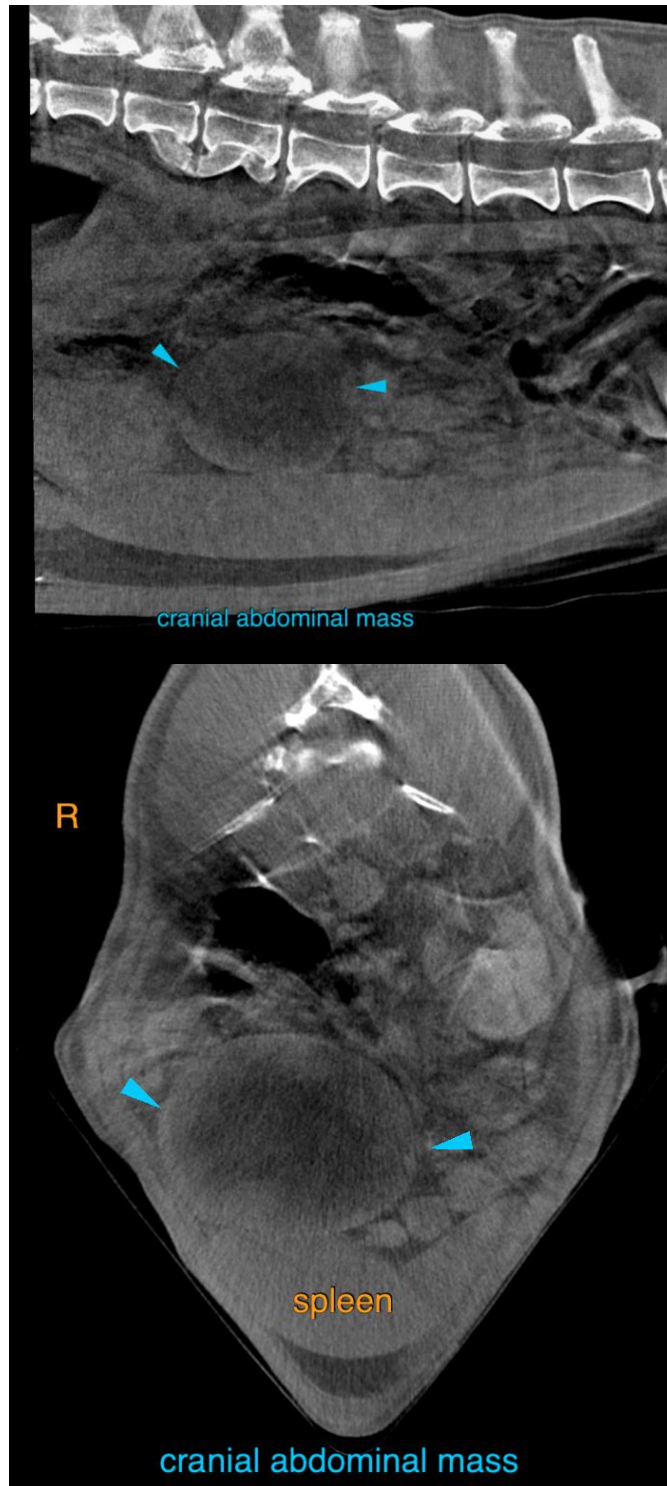North Shore Vet
Hospital

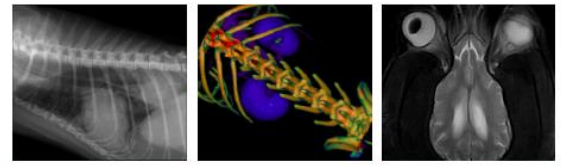
INVOICE

53947

DATE

9-6-22





PATIENT

Kiley Farrelly

SPECIES

Canine

BREED

Mix Breed

SEX

FS

AGE

13 Years

INTERPRETED BY

Sebastian Schaub, DVM
Dr. med. vet. DipECVDI

HOSPITAL NAME

Animal Surgical
Center

REFERRING VET

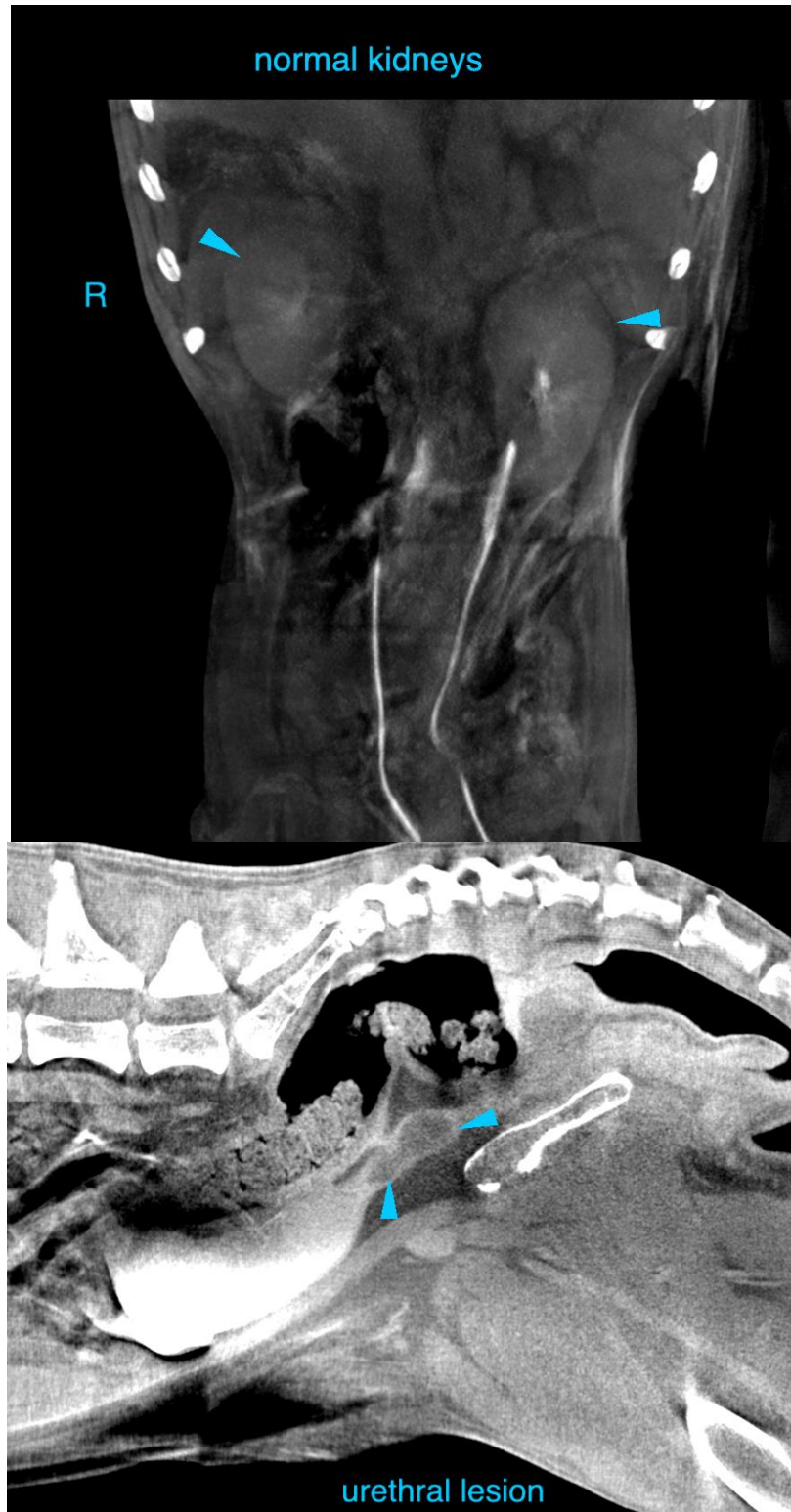
North Shore Vet
Hospital

INVOICE

53947

DATE

9-6-22





PATIENT

Kiley Farrelly

The information and recommendations provided are based on the images presented by the referring veterinarian/sonographer. No evaluation can be communicated regarding pathology that was not visible in the image/video clips provided.

SPECIES

Canine

Thank you for this referral. If the clinical or image interpretation does not parallel your findings or if I can be of any further assistance please contact me.

Sebastian Schaub, Sebastian Schaub, DVM, Dr. med. vet. DipECVDI
sebast.schaub@gmail.com

BREED

Mix Breed

SEX

FS

AGE

13 Years

INTERPRETED BY

Sebastian Schaub, DVM
Dr. med. vet. DipECVDI

HOSPITAL NAME

Animal Surgical
Center

REFERRING VET

North Shore Vet
Hospital

INVOICE

53947

DATE

9-6-22