



PATIENT

Howie Kercado

PRESENTING CLINICAL SIGNS

Patient presented to the ER last night after being HBC. Survey thoracic & abdominal radiographs acquired at presentation. Marked narrowing of L2-L3 was noted along with markedly reduced serosal detail in the abdominal cavity was noted on radiographs. Serial FAST scan showed increased retroperitoneal fluid around the left kidney. An abdominal CT, acquired in transverse plane images prior to and following intravenous administration of iodinated contrast medium is submitted for review.

SPECIES

Canine

Abnormal PE/Chem/CBC/UA Results: Slightly prolonged aPTT, persistent azotemia with mild improvement noted along with resolving hyperkalemia from presentation

BREED

Aussiedoodle,
Miniature

COMPUTED TOMOGRAPHY OF THE ABDOMEN

A high resolution pre- and post-contrast CT study of the abdomen is provided for review.

COMPUTED TOMOGRAPHIC FINDINGS

SEX

MN

The abdomen is distended and a moderate to marked amount of non-contrast enhancing soft tissue material is seen in the peritoneal cavity.

AGE

1 Year, 6 Months

The right transverse process of L3 presents a transverse fracture line at the base and the left transverse process of L3 presents a fissure line in the proximal segment.

INTERPRETED BY

Sebastian Schaub, DVM
Dr. med. vet. DipECVDI

Both kidneys present within normal limits for size, shape and organ architecture. After contrast administration a bilaterally symmetric and uniform nephro- and pyelogram is noted. A small gas bubble is seen in the lumen of the urinary bladder – likely iatrogenic due to preceding cystocentesis or catheterization. Post contrast administration contrast is oozing from the lumen of the urinary bladder into the peritoneal cavity – pooling in the dorsal dependent aspects of the peritoneal cavity. No contrast leakage from the ureters is appreciated.

HOSPITAL NAME

South Bay Animal
Hospital

The adrenal glands are within normal limits for size, shape and organ architecture.

The spleen presents with normal shape, even surface, uniformly attenuating parenchyma and homogeneous contrast enhancement, unremarkable.

The hepatic volume mildly decreased. The hepatic parenchyma is uniform soft tissue attenuating and contrast enhancing.

REFERRING VET

Ravinder Atwal, DVM,
CCRP

The pancreas is evenly contoured, the pancreatic parenchyma is homogeneous and presents uniform contrast enhancement.

The position, delineation, wall and content of the gastrointestinal tract are considered within normal limits throughout.

INVOICE

47364

A small (<5 mm) gas filled lesion presenting a well defined thin wall is seen in the periphery of the dorsal aspect of the left caudal lung lobe.

COMPUTED TOMOGRAPHIC DIAGNOSIS

DATE

9-6-21

- Ruptured urinary bladder
- Secondary marked peritoneal effusion



PATIENT

Howie Kercado

- Acute closed traumatic transverse fracture right transverse process L3 and fissure line left transverse process L3
- Suspect traumatic pneumatocele left caudal lung lobe, no evidence of peritoneal effusion
- No evidence of discopathy

SPECIES

Canine

INTERPRETATION OF THE FINDINGS & FURTHER RECOMMENDATIONS

There is traumatic rupture of the urinary bladder explaining the marked peritoneal effusion and azotemia. Surgical repair of the urinary bladder is the therapy of choice.

BREED

Aussiedoodle,
Miniature

No additional clinically relevant abnormalities are appreciated.

SEX

MN

AGE

1 Year, 6 Months

INTERPRETED BY

Sebastian Schaub, DVM
Dr. med. vet. DipECVDI

HOSPITAL NAME

South Bay Animal
Hospital

REFERRING VET

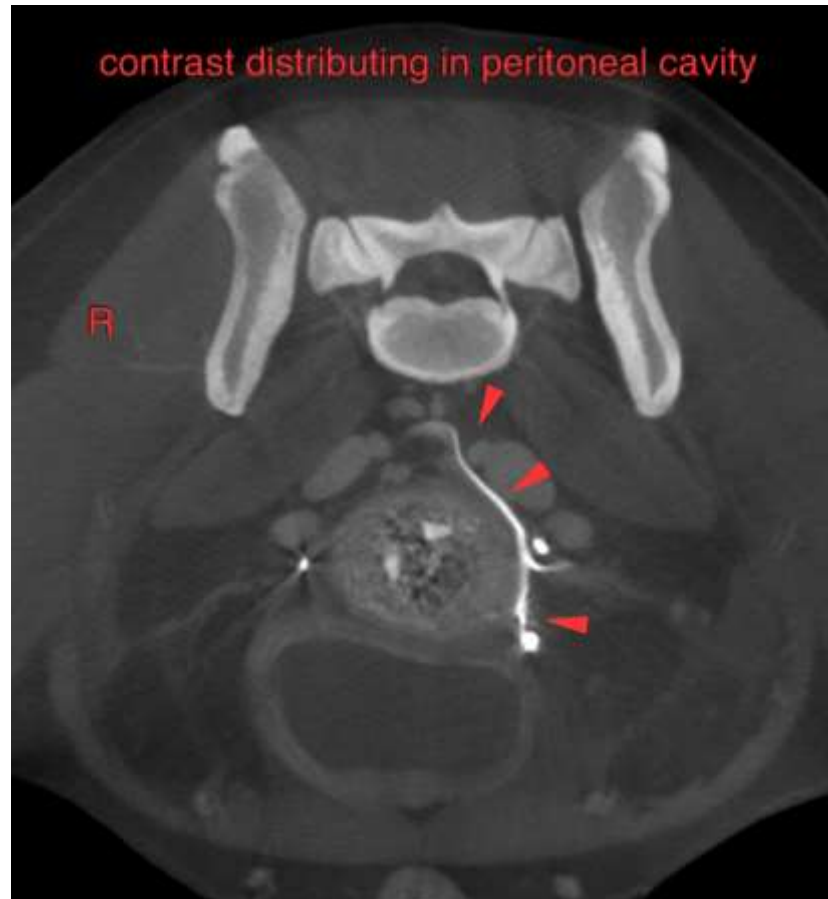
Ravinder Atwal, DVM,
CCRP

INVOICE

47364

DATE

9-6-21





PATIENT

Howie Kercado

SPECIES

Canine

BREED

Aussiedoodle,
Miniature

SEX

MN

AGE

1 Year, 6 Months

INTERPRETED BY

Sebastian Schaub, DVM
Dr. med. vet. DipECVDI

HOSPITAL NAME

South Bay Animal
Hospital

REFERRING VET

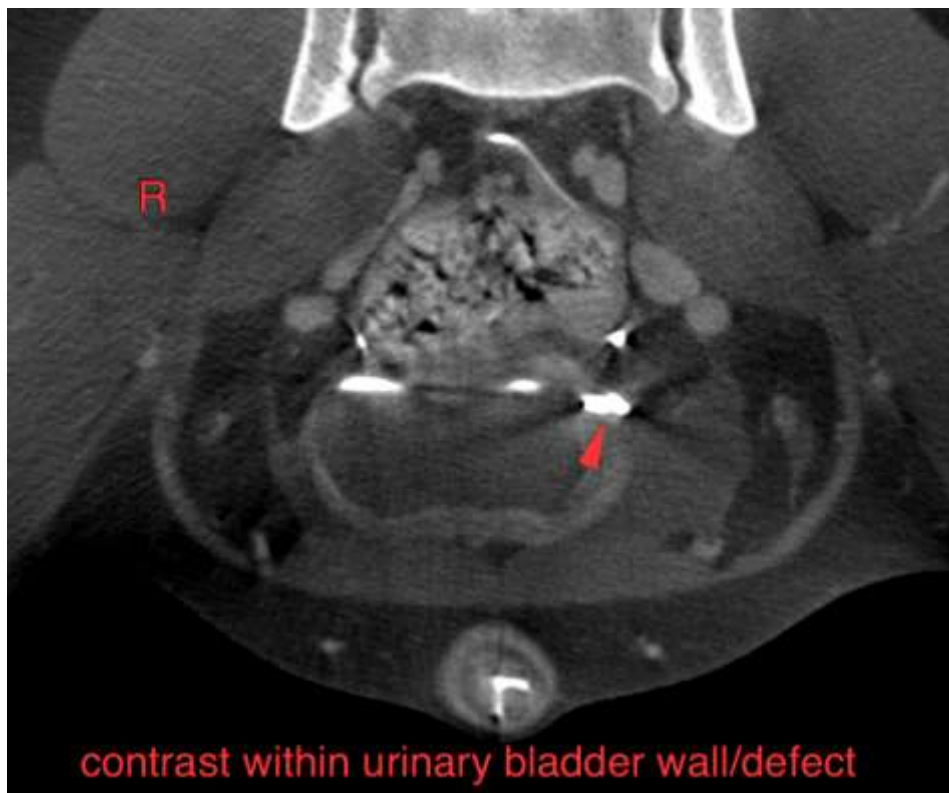
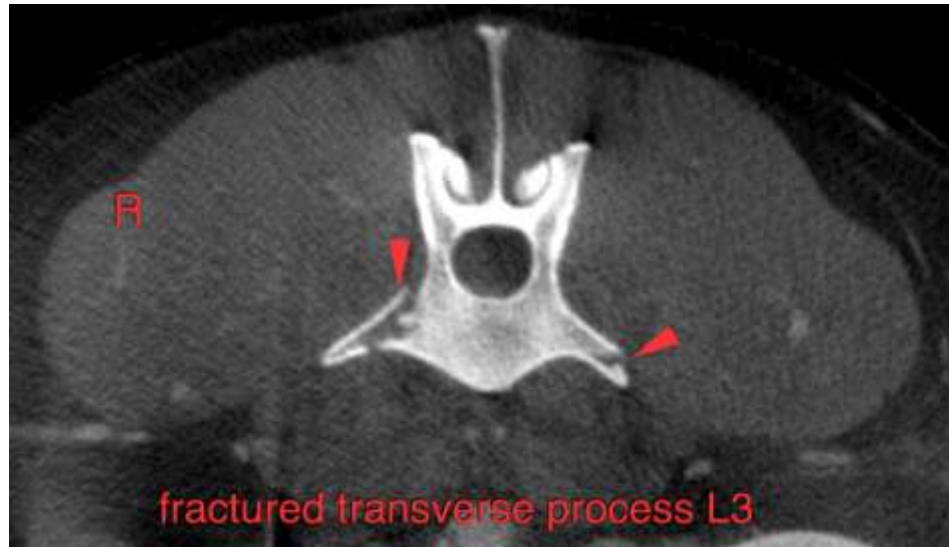
Ravinder Atwal, DVM,
CCRP

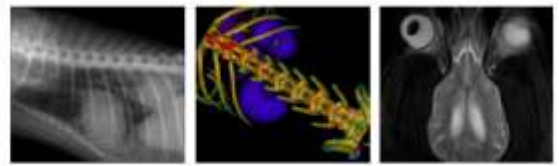
INVOICE

47364

DATE

9-6-21





PATIENT

Howie Kercado

The information and recommendations provided are based on the images presented by the referring veterinarian. No evaluation can be communicated regarding pathology that was not visible in the image/video clips provided.

Thank you for this referral. If the clinical or image interpretation does not parallel your findings or if I can be of any further assistance please contact me.

SPECIES

Canine

Sebastian Schaub, Sebastian Schaub, DVM, Dr. med. vet. DipECVDI
sebast.schaub@gmail.com

BREED

Aussiedoodle,
Miniature

SEX

MN

AGE

1 Year, 6 Months

INTERPRETED BY

Sebastian Schaub, DVM
Dr. med. vet. DipECVDI

HOSPITAL NAME

South Bay Animal
Hospital

REFERRING VET

Ravinder Atwal, DVM,
CCRP

INVOICE

47364

DATE

9-6-21