



PATIENT

Eva Figueroa

PRESENTING CLINICAL SIGNS

Referral : Thoracolumbar CT Scan Patient down in the rear
 Abnormal PE/Chem/CBC/UA Results: CBC: mild anemia, thrombocytosis CHEM: ALP 273 ,ALT 302

SPECIES

Canine

COMPUTED TOMOGRAPHY OF THE THORACIC&LUMBAR SPINE

A high resolution pre- and post-contrast CT study of the thoracic & lumbar spine is provided for review.

BREED

Chihuahua

COMPUTED TOMOGRAPHIC FINDINGS

THE LAST RIB BEARING VERTEBRA IS COUNTED AS T13.

SEX

FS

The thoracic spine including the osseous and soft tissue structures are within normal limits , but mild spondylosis formation level T4/T5.

AGE

5 Years

The intervertebral disc space L1/L2 is moderately narrowed. Mild hyperattenuating and contrast enhancing material is seen in the left ventral and lateral aspect of the vertebral canal level with the intervertebral disc space L1/L2 occupying approximately 10% of the cross-sectional area of the vertebral canal at the same level. The mild hyperattenuating material is extending caudally and cranially over the complete length of the respective vertebral bodies.

INTERPRETED BY

Sebastian Schaub, DVM
 Dr. med. vet. DipECVDI

The remainder of the lumbar spine are within normal limits.

COMPUTED TOMOGRAPHIC DIAGNOSIS

- Intervertebral disc extrusion L1/L2
- Spondylosis deformans T4/T5

HOSPITAL NAME

Veterinary Image Center

INTERPRETATION OF THE FINDINGS & FURTHER RECOMMENDATIONS

The CT study is consistent with intervertebral disc extrusion L1/L2, the amount of extruded material appears only mild, and it based on the grade of neurological deficits complementing workup by a myelographic CT study might be beneficial as both intervertebral disc extrusion or acute non-compressive nucleus pulposus extrusion are potentials here.

REFERRING VET

Dr. J. Colón

INVOICE

47351

DATE

9-6-21



PATIENT

Eva Figueroa

SPECIES

Canine

BREED

Chihuahua

SEX

FS

AGE

5 Years

INTERPRETED BY

Sebastian Schaub, DVM
Dr. med. vet. DipECVDI

HOSPITAL NAME

Veterinary Image
Center

REFERRING VET

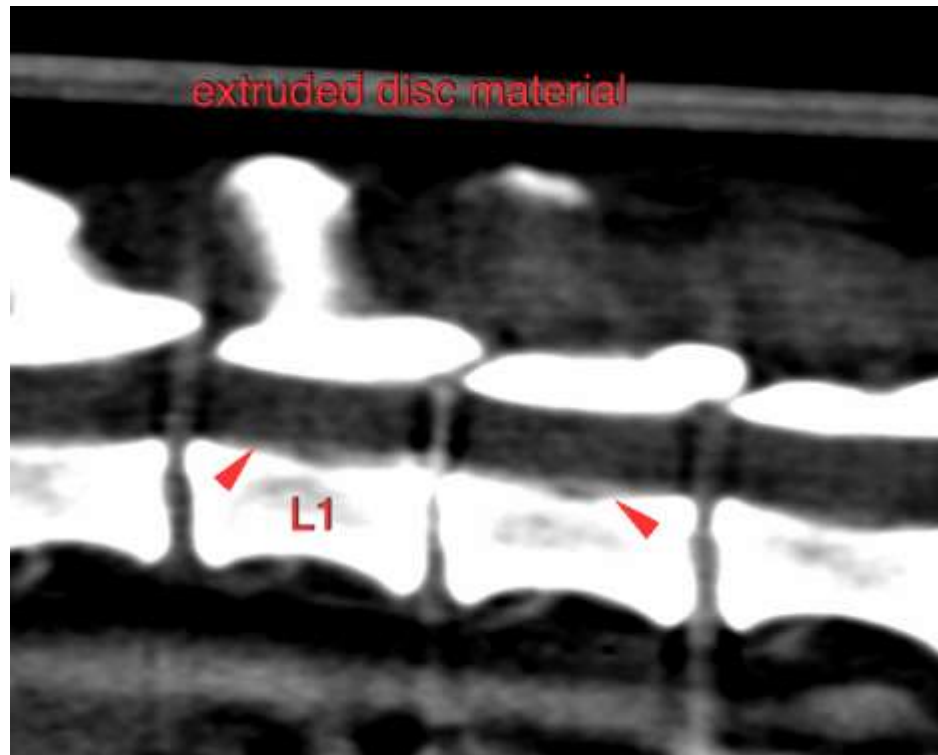
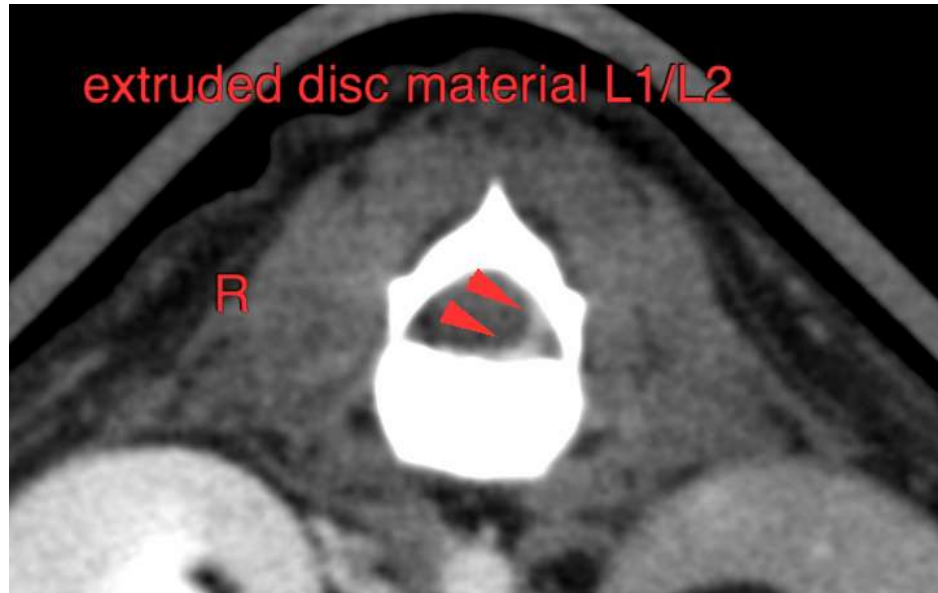
Dr. J. Colón

INVOICE

47351

DATE

9-6-21





PATIENT

Eva Figueroa

The information and recommendations provided are based on the images presented by the referring veterinarian. No evaluation can be communicated regarding pathology that was not visible in the image/video clips provided.

Thank you for this referral. If the clinical or image interpretation does not parallel your findings or if I can be of any further assistance please contact me.

SPECIES

Canine

Sebastian Schaub, Sebastian Schaub, DVM, Dr. med. vet. DipECVDI
sebast.schaub@gmail.com

BREED

Chihuahua

SEX

FS

AGE

5 Years

INTERPRETED BY

Sebastian Schaub, DVM
Dr. med. vet. DipECVDI

HOSPITAL NAME

Veterinary Image
Center

REFERRING VET

Dr. J. Colón

INVOICE

47351

DATE

9-6-21