



**PATIENT**

Cici Swaringam

**PRESENTING CLINICAL SIGNS**

Patient initially presented on 9/2 for acting abnormally. She had been quite lethargic and whining, especially when the owners touched her. She has also recently been a little slower than usual to stand up and seemed painful in her hips. Sedated radiographs revealed no gross abnormalities in the thoracic and abdominal cavities, but there was smooth new bone formation on the ventral aspect of the right ilium as well as right acetabulum and femoral neck and head. The right acetabulum was irregularly shaped. There were also ill-defined lucent regions present within the right femoral head and thickening of soft tissue surrounding the right coxofemoral joint. Concern for a polyostic aggressive bone lesion was raised and a pelvic and thoracic CT is submitted for review.

**SPECIES**

Canine

**BREED**

Mixed Breed

Abnormal PE/Chem/CBC/UA Results: slight hypomagnesemia, dec USG (1.007), and slightly dec tT4 (1.17 ug/dL)

**SEX**

FS

**COMPUTED TOMOGRAPHY OF THE THORAX AND PELVIS**

A high resolution pre- and post-contrast CT study of the thorax and pelvis are provided for review.

**AGE**

6 Years, 3 Months

Thorax

The bony and surrounding soft tissue structures are within normal limits.

**INTERPRETED BY**

Sebastian Schaub, DVM  
Dr. med. vet. DipECVDI

The sternal, cranial mediastinal and tracheobronchial lymph nodes are small elongated with a normal short-to-long-axis-ratio is < 0.5, the attenuation and contrast enhancement pattern is uniform and considered within normal limits.

The cardiovascular structures including the pulmonary vasculature are within normal limits.

**HOSPITAL NAME**

South Bay Animal  
Hospital & Pet Resort

The bronchial tree presents with regular branching and tapers uniformly towards the periphery as expected, the bronchial walls are thin and smooth. The bronchus-to-artery ratio is within normal limits.

**REFERRING VET**

Ravinder Atwal, DVM,  
CCRP

The lung parenchyma presents the expected architecture and attenuation behavior with interspersed punctuate mineralizations.

Small incidental gas pockets are seen within the esophageal lumen, there is no evidence of abnormal dilation.

**INVOICE**

47358

Pelvis

The iliosacral joints show moderate degenerative changes.

**DATE**

9-4-21

Both coxofemoral joints present moderate to marked osteophyte new bone formation. The acetabular groove bilaterally is shallow, and the center of the femoral heads is lateral to the dorsal acetabular rim.



**PATIENT**

Cici Swaringam

**COMPUTED TOMOGRAPHIC DIAGNOSIS**

- Degenerative osteoarthritis coxofemoral joints bilaterally
- Degenerative changes iliosacral joints bilaterally – incidental
- Pulmonary osteomas, no evidence of pulmonary metastatic spread

**SPECIES**

Canine

**INTERPRETATION OF THE FINDINGS & FURTHER RECOMMENDATIONS**

The findings are consistent with chronic degenerative joint disease of the coxofemoral joints bilaterally due to hip dysplasia. There is no evidence of biologically aggressive disease. Recommend empirical pain management. Intraarticular glucocorticoid application into the coxofemoral joints bilaterally can be considered as well. If the patient presents with significant clinical signs, advanced surgical procedures, might be discussed with orthopedic surgeon.

**BREED**

Mixed Breed

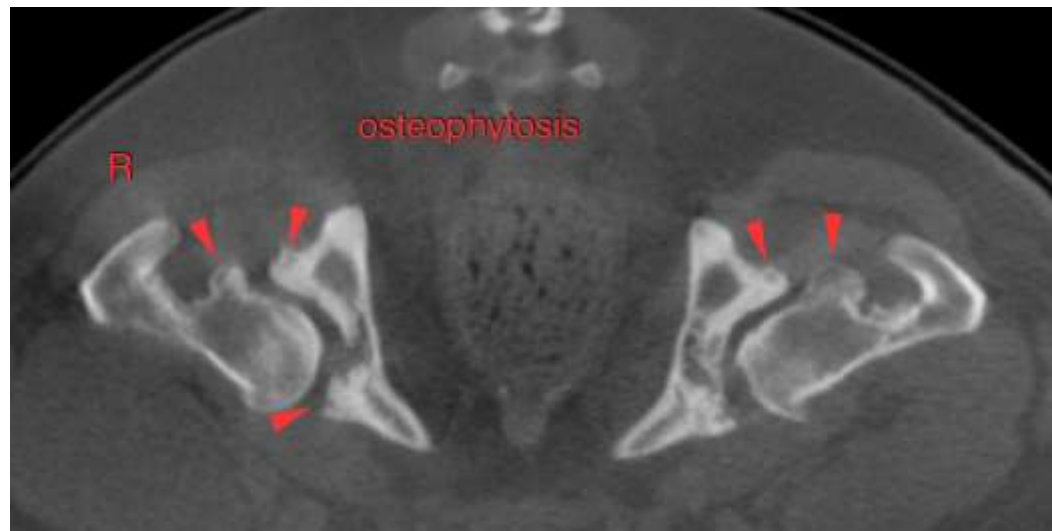
**SEX**

FS

Rule out orthopedic problems of the distal aspects of the hind limbs as well – such as pathology of the stifle joints.

**AGE**

6 Years, 3 Months



**INTERPRETED BY**

Sebastian Schaub, DVM  
Dr. med. vet. DipECVDI

**HOSPITAL NAME**

South Bay Animal  
Hospital & Pet Resort

**REFERRING VET**

Ravinder Atwal, DVM,  
CCRP

The information and recommendations provided are based on the images presented by the referring veterinarian. No evaluation can be communicated regarding pathology that was not visible in the image/video clips provided.

**INVOICE**

47358

Thank you for this referral. If the clinical or image interpretation does not parallel your findings or if I can be of any further assistance please contact me.

**DATE**

9-4-21

**Sebastian Schaub**, Sebastian Schaub, DVM, Dr. med. vet. DipECVDI  
sebast.schaub@gmail.com