



PATIENT

Sierra Dog Tales
Rescue

PRESENTING CLINICAL SIGNS

Owner notice a lump over her throat a month ago. FNA suspected thyroid carcinoma. Other lumps noted are lipomas Owners report she is losing a lot of weight, even before the mass was noticed. Eating and drinking normal, not on any medications. On a Gastro diet. Activity is normal, still runs around Pre and post contrast CT scan performed Sept 30th 2021 of Neck and chest
Abnormal PE/Chem/CBC/UA Results: Mid lumbar back pain. elbow crepitus

SPECIES

Canine

COMPUTED TOMOGRAPHY OF THE NECK AND THORAX

A pre- and post-contrast CT study of the neck and thorax in a bone, lung and soft tissue reconstruction are provided for review.

BREED

Siberian Husky

COMPUTED TOMOGRAPHIC FINDINGS

Neck

SEX

Both external ear canals present moderate dystrophic mineralization.

FS

AGE

12 Years

Originating from the right thyroid gland, a well-defined, heterogeneous soft tissue attenuating (28 HU) mass is visible, measuring 2.6 cm in diameter and 4.0 cm in size. Post contrast administration the right thyroid mass presents marked peripheral contrast enhancement with a hypoattenuating center. Post contrast administration multiple small tortuous feeding vessels are seen in the periphery of the right thyroid mass. The right common carotid artery is displaced dorsally by the mass effect.

INTERPRETED BY

Sebastian Schaub, DVM
Dr. med. vet. DipECVDI

The vertebral endplates C6/C7 present mild spondylosis formation.

Thorax

HOSPITAL NAME

Animal Health
Partners

Level with the 3rd and 4th right rib, an ovoid shaped lipoma is seen in the subcutaneous tissue at the craniolateral aspect of the right thoracic wall. The sternum presents moderate degenerative changes. The pictured parts of the front limbs are within normal limits.

The sternal, cranial mediastinal and tracheobronchial lymph nodes are small elongated with a normal short-to-long-axis-ratio is < 0.5, the attenuation and contrast enhancement pattern is uniform and considered within normal limits.

REFERRING VET

Dr. Jeffery Biskup

The cardiovascular structures including the pulmonary vasculature are within normal limits.

The bronchial tree presents with regular branching and tapers uniformly towards the periphery as expected, the bronchial walls are thin and smooth. The bronchus-to-artery ratio is within normal limits.

INVOICE

47608

The lung parenchyma presents the expected architecture and attenuation behavior.

Small incidental gas pockets are seen within the esophageal lumen, there is no evidence of abnormal dilation.

DATE

9-30-21



PATIENT

Sierra Dog Tales
Rescue

SPECIES

Canine

BREED

Siberian Husky

SEX

FS

AGE

12 Years

INTERPRETED BY

Sebastian Schaub, DVM
Dr. med. vet. DipECVDI

HOSPITAL NAME

Animal Health
Partners

REFERRING VET

Dr. Jeffery Biskup

INVOICE

47608

DATE

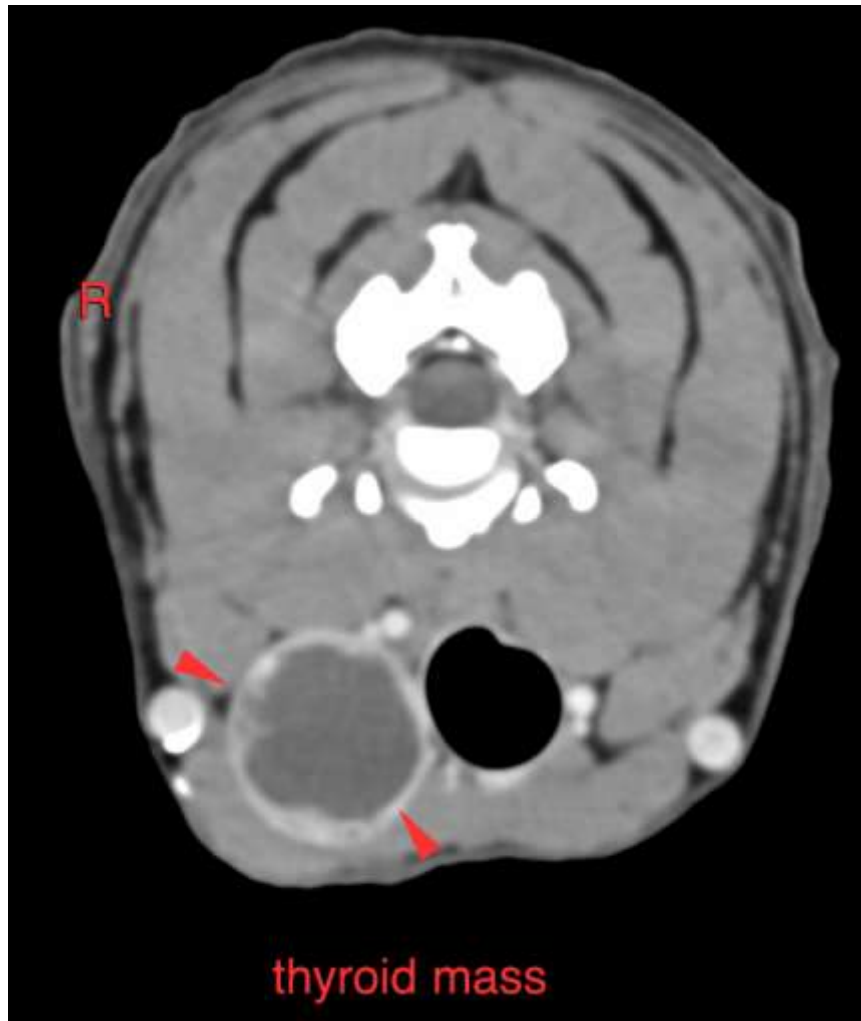
9-30-21

COMPUTED TOMOGRAPHIC DIAGNOSIS

- Cavitated right thyroid mass without evidence of vascular invasion
- Small subcutaneous lipoma right cranioventral thoracic wall
- No evidence of pulmonary metastatic disease
- Spondylosis deformans C6/C7

INTERPRETATION OF THE FINDINGS & FURTHER RECOMMENDATIONS

The CT study support the diagnosis of right sided cavitated thyroid carcinoma, there is no evidence of vascular invasion and complete surgical excision of the mass appears feasible. If not done so yet, complementing workup by blood T4 level can be used to check for functional carcinoma as potential source for the weight loss.





PATIENT

Sierra Dog Tales
Rescue

SPECIES

Canine

BREED

Siberian Husky

SEX

FS

AGE

12 Years

INTERPRETED BY

Sebastian Schaub, DVM
Dr. med. vet. DipECVDI

HOSPITAL NAME

Animal Health
Partners

REFERRING VET

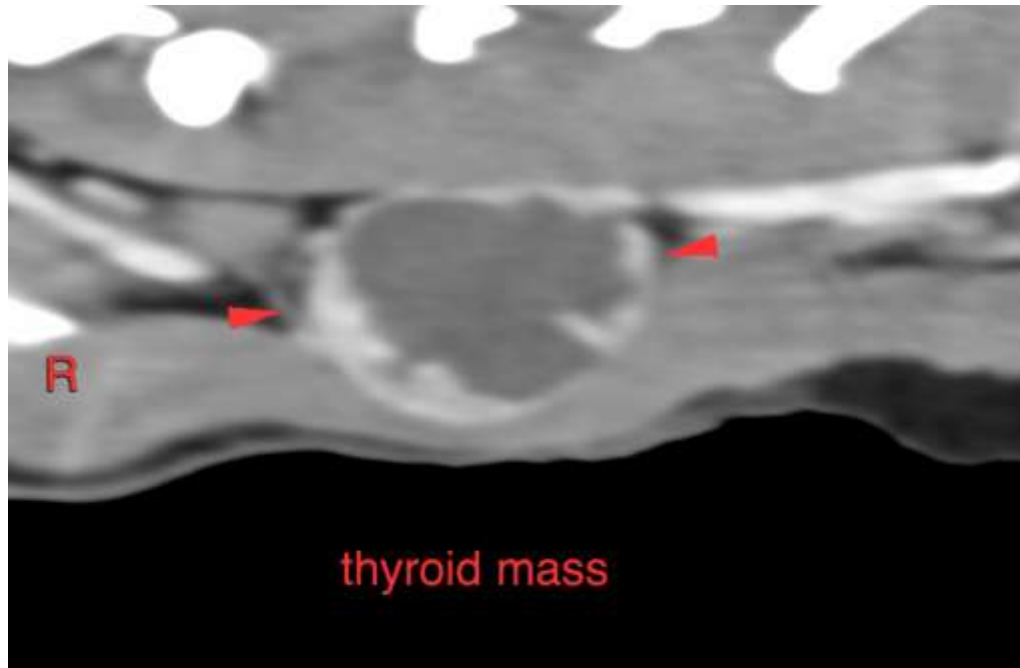
Dr. Jeffery Biskup

INVOICE

47608

DATE

9-30-21



The information and recommendations provided are based on the images presented by the referring veterinarian. No evaluation can be communicated regarding pathology that was not visible in the image/video clips provided.

Thank you for this referral. If the clinical or image interpretation does not parallel your findings or if I can be of any further assistance please contact me.

Sebastian Schaub, Sebastian Schaub, DVM, Dr. med. vet. DipECVDI
sebast.schaub@gmail.com