



PATIENT PRESENTING CLINICAL SIGNS

Teller Brodsky History: Acutely painful around lower back. Started today.

Abnormal PE/Chem/CBC/UA Results:

SPECIES

Canine

RADIOGRAPHIC STUDY OF THE LUMBAR SPINE

A laterolaterale projection of the lumbar spine is provided for review.

BREED

Shepherd Mix

RADIOGRAPHIC FINDINGS

Generalized bridging spondylosis formation is seen along the thoracolumbar junction and caudal lumbar spine. Generalized smooth bone formation is seen between the spinous processes of the lumbar spine and the facet joints of the lumbar spine are ill-defined with smooth new bone formation.

SEX

Spayed Female

RADIOGRAPHIC DIAGNOSIS

- Diffuse idiopathic skeletal hyperostosis of the lumbar spine

AGE

4 Years 3 Months

INTERPRETATION OF THE FINDINGS & FURTHER RECOMMENDATIONS

The radiographic study is consistent with diffuse idiopathic skeletal hyperostosis of the lumbar spine, commonly the findings are progressive with age and not related with clinical signs or the patients present only mild clinical signs. However, the disease can predispose for discopathy of unfused vertebral segments. Pain management and physical therapy are considered as the preferred treatment options at this point. If neurological deficits develop or signs are refractory to therapy, cross-sectional imaging is recommended.

INTERPRETED BY

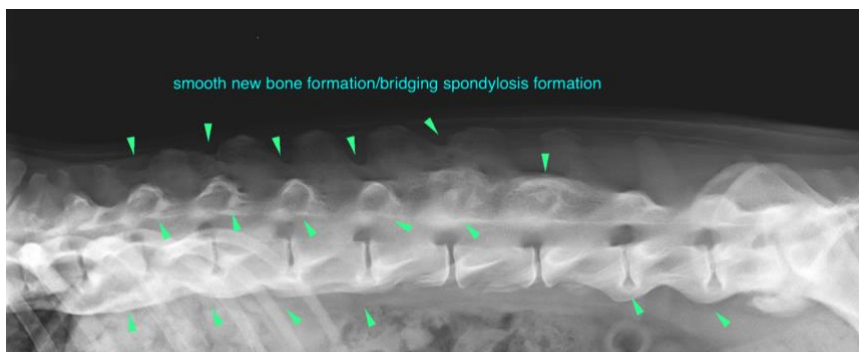
Sebastian Schaub,
DVM Dr. med. vet.
DipECVDI

HOSPITAL NAME

All Creatures AH of
SH

REFERRING VET

Dr. Pam Wiltizius



INVOICE

13342

The information and recommendations provided are based on the images presented by the referring veterinarian. No evaluation can be communicated regarding pathology that was not visible in the image/video clips provided.

DATE

9/28/21



PATIENT

Thank you for this referral. If the clinical or image interpretation does not parallel your findings or if I can be of any further assistance please contact me.

Teller Brodsky

Sebastian Schaub, Sebastian Schaub, DVM, Dr. med. vet. DipECVDI
sebast.schaub@gmail.com

SPECIES

Canine

BREED

Shepherd Mix

SEX

Spayed Female

AGE

4 Years 3 Months

INTERPRETED BY

Sebastian Schaub,
DVM Dr. med. vet.
DipECVDI

HOSPITAL NAME

All Creatures AH of
SH

REFERRING VET

Dr. Pam Wiltizius

INVOICE

13342

DATE

9/28/21