



PATIENT PRESENTING CLINICAL SIGNS

Louie Reif History: Acute respiratory effort for two weeks. Left side anal mass
Abnormal PE/Chem/CBC/UA Results:

SPECIES RADIOGRAPHIC STUDY OF THE THORAX

Canine Radiographs of the thorax in three imaging planes are provided for review.

RADIOGRAPHIC FINDINGS

BREED

Pomeranian

The surrounding bony structures are within normal limits.

A faint roundish mineralization is seen in the subcutaneous tissue at the caudodorsal aspect of the neck.

SEX

Neutered Male

The heart is of normal size and shape, there is no evidence of cardiac chamber or vascular enlargement. The pulmonary vasculature is within normal limits.

AGE

8 Years

The cranial mediastinum presents the expected soft tissue opacity. The mediastinal width is less than twice the width of the vertebral column at the same level.

The trachea is normal in diameter and presents the anticipated course. The luminal outline of the trachea is smooth.

INTERPRETED BY

Sebastian Schaub,
DVM Dr. med. vet.
DipECVDI

The lung parenchyma presents generalized patchy increased soft tissue opacity caused by an unstructured reticular pattern.

The diaphragm is well delineated with even surface and the expected mild cranial bulging of the diaphragmatic cupola.

HOSPITAL NAME

Bergan County VC

RADIOGRAPHIC DIAGNOSIS

- Multifocal patchy unstructured interstitial pattern with mild bronchial component

REFERRING VET

Dr. Moore

INTERPRETATION OF THE FINDINGS & FURTHER RECOMMENDATIONS

Potentials for the lung pattern include bacterial/viral pneumonia, parasitic pneumonia (e.g. Angiostrongylus, Toxoplasmosis), acute respiratory distress syndrome (e.g. pancreatitis), pulmonary hemorrhage, neoplasia (e.g. carcinoma). If not done so yet, complementing workup by complete blood work is indicated to screen for potential inflammatory changes. A transtracheal wash can be used as an advanced diagnostic test as well. FNA sampling of the lung can be performed as an advanced diagnostic test as well.

INVOICE

13344

DATE

9/28/21



PATIENT

Louie Reif

SPECIES

Canine

BREED

Pomeranian

SEX

Neutered Male

AGE

8 Years

INTERPRETED BY

Sebastian Schaub,
DVM Dr. med. vet.
DipECVDI

HOSPITAL NAME

Bergan County VC

REFERRING VET

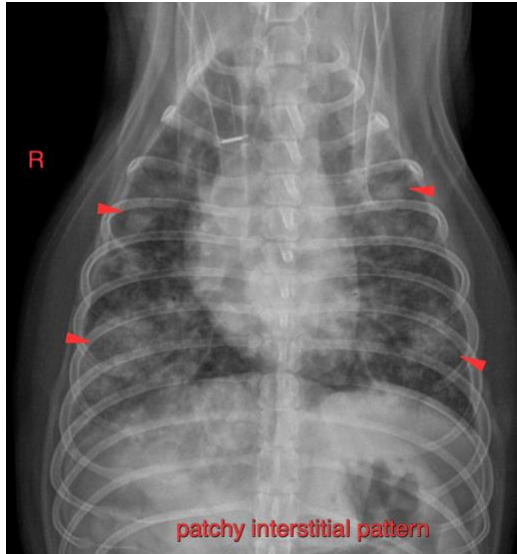
Dr. Moore

INVOICE

13344

DATE

9/28/21



The information and recommendations provided are based on the images presented by the referring veterinarian. No evaluation can be communicated regarding pathology that was not visible in the image/video clips provided.

Thank you for this referral. If the clinical or image interpretation does not parallel your findings or if I can be of any further assistance please contact me.

Sebastian Schaub, Sebastian Schaub, DVM, Dr. med. vet. DipECVDI
sebast.schaub@gmail.com