



PATIENT PRESENTING CLINICAL SIGNS

Aayla Robinson Under ophthalmologist care after inured Left eye 3-4 weeks ago. Improving at this time. Refer to the attached reports.

SPECIES COMPUTED TOMOGRAPHY OF THE SKULL

Canine A high resolution pre- and post-contrast CT study of the skull is provided for review.

BREED COMPUTED TOMOGRAPHIC FINDINGS

Pomeranian The tooth elements 305, 311, 405 and 411 are absent. A persistent deciduous tooth 504, 604 and 704 are appreciated.

SEX Both ocular bulbs appear normal, the retrobulbar space bilaterally is within normal limits.

Intact Female Both temporomandibular joints present congruent joint spaces with even subchondral bone surfaces and are considered within normal limits.

AGE Both tympanic bullae are aerated, the mucosal lining is not seen, the bony wall is smooth and thin. The external ear canals are within normal limits.

8 Months The brain presents no deviation from normal anatomy and symmetry. The brain parenchyma is homogeneous and within normal limits for attenuation and distribution of contrast enhancement. The ventricular system is non-dilated and symmetric. A keyhole malformation of the foramen magnum is present. Incomplete fusion of the sutures of the skull is appreciated.

INTERPRETED BY

Sebastian Schaub, DVM
Dr. med. vet. DipECVDI

The submandibular and medial retropharyngeal lymph nodes are small and elongated with a normal short-to-long-axis-ratio is < 0.5, the attenuation and contrast enhancement pattern is uniform.

HOSPITAL NAME

Mobile Pet Imaging

COMPUTED TOMOGRAPHIC DIAGNOSIS

- Persistent deciduous teeth
- Incomplete ossification sutures of the skull & keyhole malformation of the foramen magnum
- Normal retrobulbar space bilaterally

REFERRING VET INTERPRETATION OF THE FINDINGS & FURTHER RECOMMENDATIONS

Meaux The CT study of the skull presents without clinically relevant pathologies, no aggressive bone lesion is appreciated nor signs of retrobulbar pathology.

INVOICE

54316

DATE

9-27-22



PATIENT

Aayla Robinson

SPECIES

Canine

BREED

Pomeranian

SEX

Intact Female

AGE

8 Months

INTERPRETED BY

Sebastian Schaub, DVM
Dr. med. vet. DipECVDI

HOSPITAL NAME

Mobile Pet Imaging

REFERRING VET

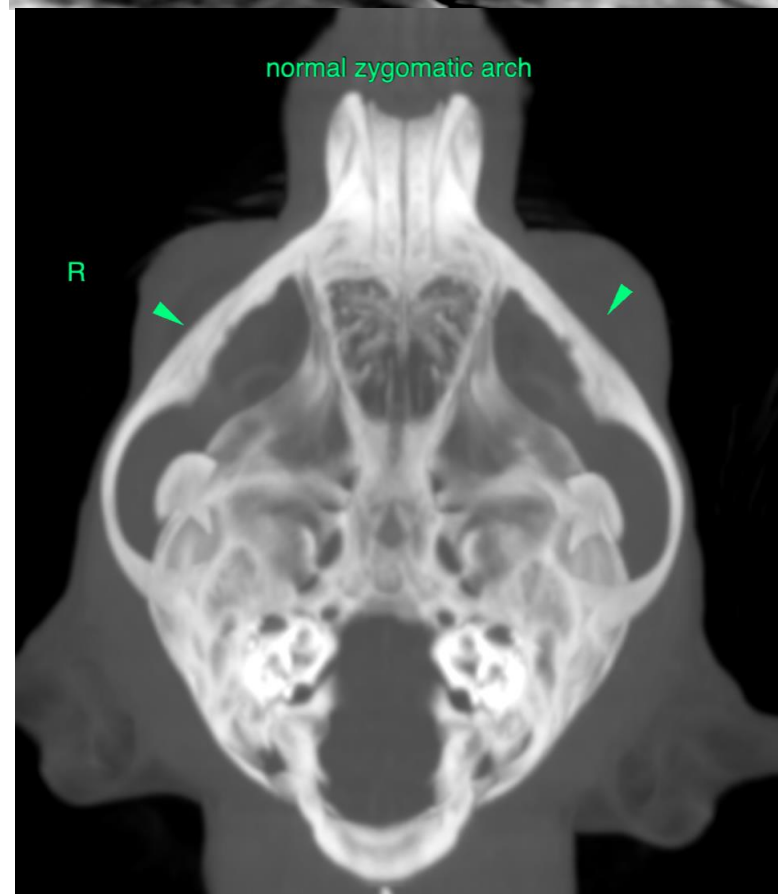
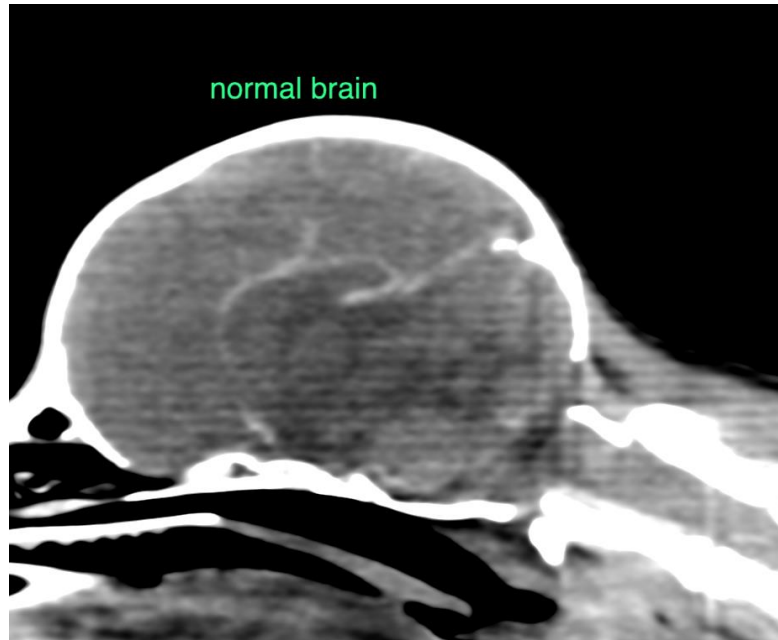
Meaux

INVOICE

54316

DATE

9-27-22





PATIENT

Aayla Robinson

SPECIES

Canine

The information and recommendations provided are based on the images presented by the referring veterinarian/sonographer. No evaluation can be communicated regarding pathology that was not visible in the image/video clips provided.

Thank you for this referral. If the clinical or image interpretation does not parallel your findings or if I can be of any further assistance please contact me.

BREED

Pomeranian

Sebastian Schaub, Sebastian Schaub, DVM, Dr. med. vet. DipECVDI
sebast.schaub@gmail.com

SEX

Intact Female

AGE

8 Months

INTERPRETED BY

Sebastian Schaub, DVM
Dr. med. vet. DipECVDI

HOSPITAL NAME

Mobile Pet Imaging

REFERRING VET

Meaux

INVOICE

54316

DATE

9-27-22