



PATIENT PRESENTING CLINICAL SIGNS

Roxie Callahan History: intermittent shifting leg lameness
Abnormal PE/Chem/CBC/UA Results:

SPECIES RADIOGRAPHIC STUDY OF THE PELVIS AND STIFLE JOINTS

Canine Radiographs of the pelvis in a ventrodorsal projection and the stifle joints in a ventrodorsal and mediolateral view are provided for review.

BREED RADIOGRAPHIC FINDINGS

Terrier Mix Only one radiograph of the stifle joints contains a sidemarker (R) and is considered as the mediolateral projection of the right stifle joint. The mediolateral view of the stifle joint without sidemarker is considered as the left stifle joint.

SEX

Spayed Female At least 12 mineral opaque calculi are seen in the imaging plane of the urinary bladder.
The osseous of the pelvis – including the coxofemoral joints – are within normal limits.

AGE

9 Years The patella of the right stifle joint is superimposed on the medial femoral condyle.
The left stifle joint presents a moderate intracapsular soft tissue swelling.

INTERPRETED BY

Both stifle joints present mild osteophyte new bone formation.

Sebastian Schaub,
DVM Dr. med. vet.
DipECVDI

RADIOGRAPHIC DIAGNOSIS

- Right sided medial patellar luxation
- Articular swelling left stifle joint
- Mild degenerative osteoarthritis stifle joints bilaterally
- Cystolithiasis

HOSPITAL NAME

Rockaway AH

INTERPRETATION OF THE FINDINGS & FURTHER RECOMMENDATIONS

REFERRING VET

Dr. Maniar

The articular swelling of the left stifle joint is compatible with joint effusion and underlying pathology of the cranial cruciate ligament or medial patellar luxation need to be considered as potential causes. The right stifle joint presents evidence of medial patellar luxation.

INVOICE

13301

Recommend clinical assessment of the grade of patellar luxation and check if the left stifle joints present with a positive drawer sign or tibial compression test under general anesthesia.

Consider a complete urinalysis for further workup of the cystolithiasis.

DATE

9/27/21



PATIENT

Roxie Callahan

SPECIES

Canine

BREED

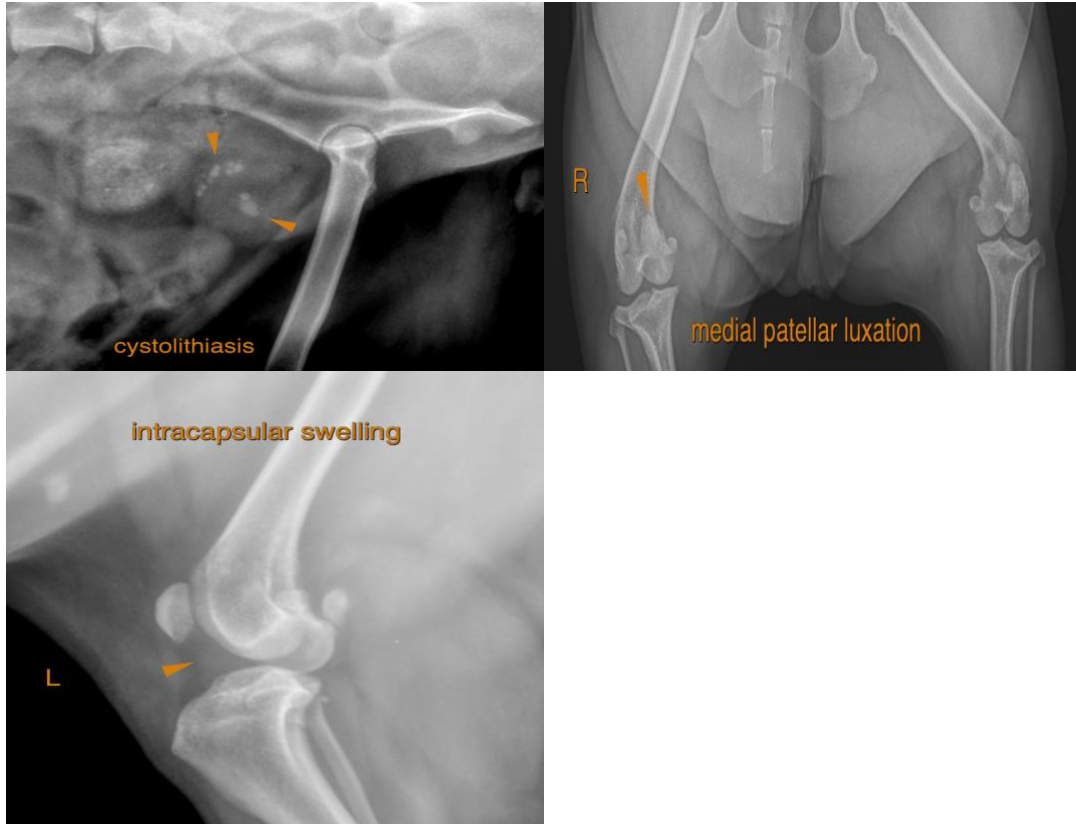
Terrier Mix

SEX

Spayed Female

AGE

9 Years



INTERPRETED BY

Sebastian Schaub,
DVM Dr. med. vet.
DipECVDI

The information and recommendations provided are based on the images presented by the referring veterinarian. No evaluation can be communicated regarding pathology that was not visible in the image/video clips provided.

HOSPITAL NAME

Rockaway AH

Thank you for this referral. If the clinical or image interpretation does not parallel your findings or if I can be of any further assistance please contact me.

Sebastian Schaub, Sebastian Schaub, DVM, Dr. med. vet. DipECVDI
sebast.schaub@gmail.com

REFERRING VET

Dr. Maniar

INVOICE

13301

DATE

9/27/21