



PATIENT PRESENTING CLINICAL SIGNS

Coco Delogu History: Severe neck pain for 72 hours
Abnormal PE/Chem/CBC/UA Results:

SPECIES RADIOGRAPHIC STUDY OF THE THORAX AND NECK

Canine Radiographs of the thorax including the cervical spine in three imaging planes are provided for review.

BREED RADIOGRAPHIC FINDINGS

Terrier, Soft Coated Wheaten The intervertebral disc space C4/C5 is mildly narrowed. No additional abnormalities of the osseous structures of the neck and thorax are noted.

SEX Two small irregular mineralization's are seen in the subcutaneous tissue at the dorsal aspect of the neck, measuring up to 7 mm in size.

Spayed Female The heart is of normal size and shape, there is no evidence of cardiac chamber or vascular enlargement. The pulmonary vasculature is within normal limits.

AGE The cranial mediastinum presents the expected soft tissue opacity. The mediastinal width is less than twice the width of the vertebral column at the same level.

9 Years The trachea is normal in diameter and presents the anticipated course. The luminal outline of the trachea is smooth.

INTERPRETED BY

Sebastian Schaub, DVM Dr. med. vet. DipECVDI The bronchial tree presents with thin walls and tapers uniformly towards the periphery as expected. The lung parenchyma presents the expected architecture and opacity; the intrapulmonary vascular branching is seen up to the third order lung vessels.

HOSPITAL NAME

St. Catharine's AH The diaphragm is well delineated with even surface and the expected mild cranial bulging of the diaphragmatic cupola.

RADIOGRAPHIC DIAGNOSIS

REFERRING VET

- Dr. Boctor
- Possible discopathy C4/C5
 - Subcutaneous dystrophic mineralizations dorsal aspect of the neck
 - Normal thorax

INTERPRETATION OF THE FINDINGS & FURTHER RECOMMENDATIONS

INVOICE

13295 The mild narrowing of the intervertebral disc space C4/C5 can indicate discopathy, however cross-sectional imaging (CT versus MRI) is warranted to check for underlying compressive myelopathy.

DATE

9/27/21



PATIENT

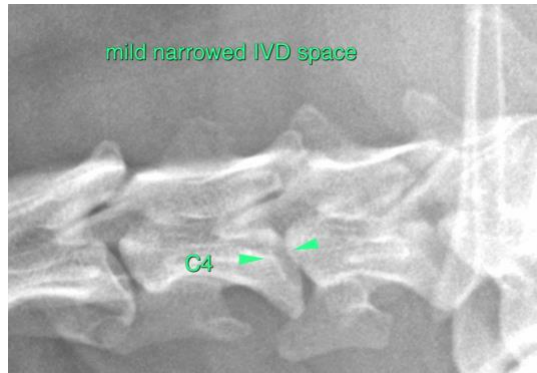
Coco Delogu

SPECIES

Canine

BREED

Terrier, Soft Coated
Wheaten



The information and recommendations provided are based on the images presented by the referring veterinarian. No evaluation can be communicated regarding pathology that was not visible in the image/video clips provided.

SEX

Spayed Female

Thank you for this referral. If the clinical or image interpretation does not parallel your findings or if I can be of any further assistance please contact me.

AGE

9 Years

Sebastian Schaub, Sebastian Schaub, DVM, Dr. med. vet. DipECVDI
sebast.schaub@gmail.com

INTERPRETED BY

Sebastian Schaub,
DVM Dr. med. vet.
DipECVDI

HOSPITAL NAME

St. Catharine's AH

REFERRING VET

Dr. Boctor

INVOICE

13295

DATE

9/27/21