



PATIENT PRESENTING CLINICAL SIGNS

Buddy Tuski History: chronic cough. known heart condition and on cardiac medication but want to determine if there is concurrent bronchitis

SPECIES Abnormal PE/Chem/CBC/UA Results: no current lab work

Canine RADIOGRAPHIC STUDY OF THE THORAX

Radiographs of the thorax in three imaging planes are provided for review.

BREED RADIOGRAPHIC FINDINGS

Chihuahua The VD projection of the thorax is moderately rotated.

SEX Both shoulder joints present mild osteophyte new bone formation.

Neutered Male The extrathoracic soft tissues present homogeneous without abnormalities.

AGE The caudal contour of the cardiac silhouette is steep and moderate bulging of the left atrium is appreciated. The left ventricle is elongated in the VD projection. The pulmonary vasculature is within normal limits.

11 Years The cranial mediastinum presents the expected soft tissue opacity. The mediastinal width is less than twice the width of the vertebral column at the same level.

INTERPRETED BY

Sebastian Schaub, DVM Dr. med. vet. DipECVDI The trachea is normal in diameter and presents the anticipated course. The luminal outline of the trachea is smooth.

HOSPITAL NAME

The bronchial tree presents with thin walls and tapers uniformly towards the periphery as expected. The lung parenchyma presents the expected architecture and opacity; the intrapulmonary vascular branching is seen up to the third order lung vessels.

Q Street AH

The diaphragm is well delineated with even surface and the expected mild cranial bulging of the diaphragmatic cupola.

REFERRING VET

RADIOGRAPHIC DIAGNOSIS

Bret Schneider

- Left sided cardiomegaly without signs for decompensation
- Mild degenerative osteoarthritis shoulder joints bilaterally

INVOICE

13304

INTERPRETATION OF THE FINDINGS & FURTHER RECOMMENDATIONS

DATE

9/27/21



PATIENT

Buddy Tuski

Besides the known cardiac changes – suspect myxomatous mitral valve degeneration with secondary mitral valve insufficiency and left cardiac volume overload – no additional clinically relevant abnormalities are appreciated. However, negative radiographs do not rule out bronchitis completely.

SPECIES

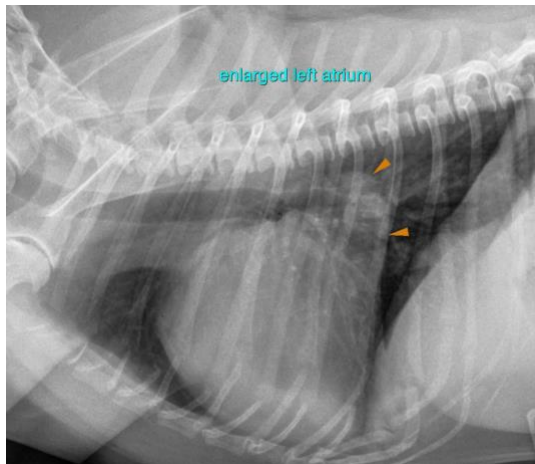
Canine

BREED

Chihuahua

SEX

Neutered Male



AGE

11 Years

The information and recommendations provided are based on the images presented by the referring veterinarian. No evaluation can be communicated regarding pathology that was not visible in the image/video clips provided.

Thank you for this referral. If the clinical or image interpretation does not parallel your findings or if I can be of any further assistance please contact me.

INTERPRETED BY

Sebastian Schaub,
DVM Dr. med. vet.
DipECVDI

Sebastian Schaub, Sebastian Schaub, DVM, Dr. med. vet. DipECVDI
sebast.schaub@gmail.com

HOSPITAL NAME

Q Street AH

REFERRING VET

Bret Schneider

INVOICE

13304

DATE

9/27/21