SonoPath Teleradiology

EDUCATIONAL TELECONSULTATION SERVICES™

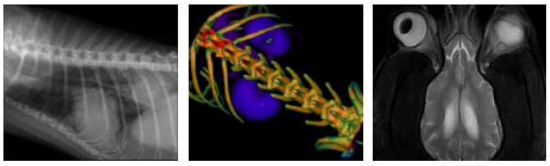

SonoPath.com
1-800-838-4268 info@sonopath.com

PATIENT

Gizmo Amato

SPECIES

Feline

BREED

DSH

SEX

SF

AGE

15 Years

INTERPRETED BY

Sebastian Schaub, DVM
Dr. med. vet. DipECVDI

HOSPITAL NAME

Long Valley Animal Hospital

REFERRING VET

Dr. Stephanie Welch

INVOICE

54265

DATE

9-26-22

PRESENTING CLINICAL SIGNS

Recent onset of non-productive cough (1-2x daily). Also recent hx of increased drinking. O has found some hairballs but does not think it is this cat (has 9 other cats). NOSF on PE or history.
Abnormal PE/Chem/CBC/UA Results: Pending - submitted today.

RADIOGRAPHIC STUDY OF THE THORAX

Radiographs of the thorax in two imaging planes are provided for review.

RADIOGRAPHIC FINDINGS

The body condition score is 8/9.

Multifocal mild spondylosis formation is seen along the caudal thoracic spine.

The extrathoracic soft tissues present homogeneous without abnormalities.

The heart is of normal size and shape, there is no evidence of cardiac chamber or vascular enlargement. The pulmonary vasculature is within normal limits.

The mediastinum is moderately widened by fat.

The trachea is normal in diameter and presents the anticipated course. The luminal outline of the trachea is smooth.

Mild thickening of the bronchial walls is appreciated.

The lung parenchyma presents the expected architecture and opacity; the intrapulmonary vascular branching is seen up to the third order lung vessels.

The diaphragm is well delineated with even surface and the expected mild cranial bulging of the diaphragmatic cupola.

RADIOGRAPHIC DIAGNOSIS

- Obesity with widening of the mediastinum
- Mild bronchial pattern
- Spondylosis deformans

INTERPRETATION OF THE FINDINGS & FURTHER RECOMMENDATIONS

The mild bronchial pattern in combination with the clinical signs is most suggestive for bronchitis, due to the recent onset of clinical signs I considered the odds for infectious origin – viral, bacterial, Mycoplasma, protozoal – higher than for allergic origin.

TECHNICAL COMMENTS

Human fingers are seen in the primary beam, please consider radiation safety guidelines!

SonoPath Teleradiology

EDUCATIONAL TELECONSULTATION SERVICES™

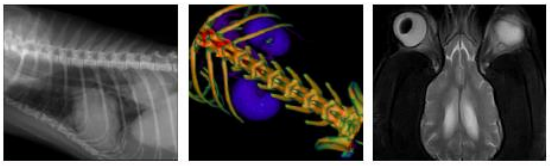

SonoPath.com
1-800-838-4268 info@sonopath.com

PATIENT

Gizmo Amato

SPECIES

Feline

BREED

DSH

SEX

SF

AGE

15 Years

INTERPRETED BY

Sebastian Schaub, DVM
Dr. med. vet. DipECVDI

HOSPITAL NAME

Long Valley Animal Hospital

REFERRING VET

Dr. Stephanie Welch

INVOICE

54265

DATE

9-26-22

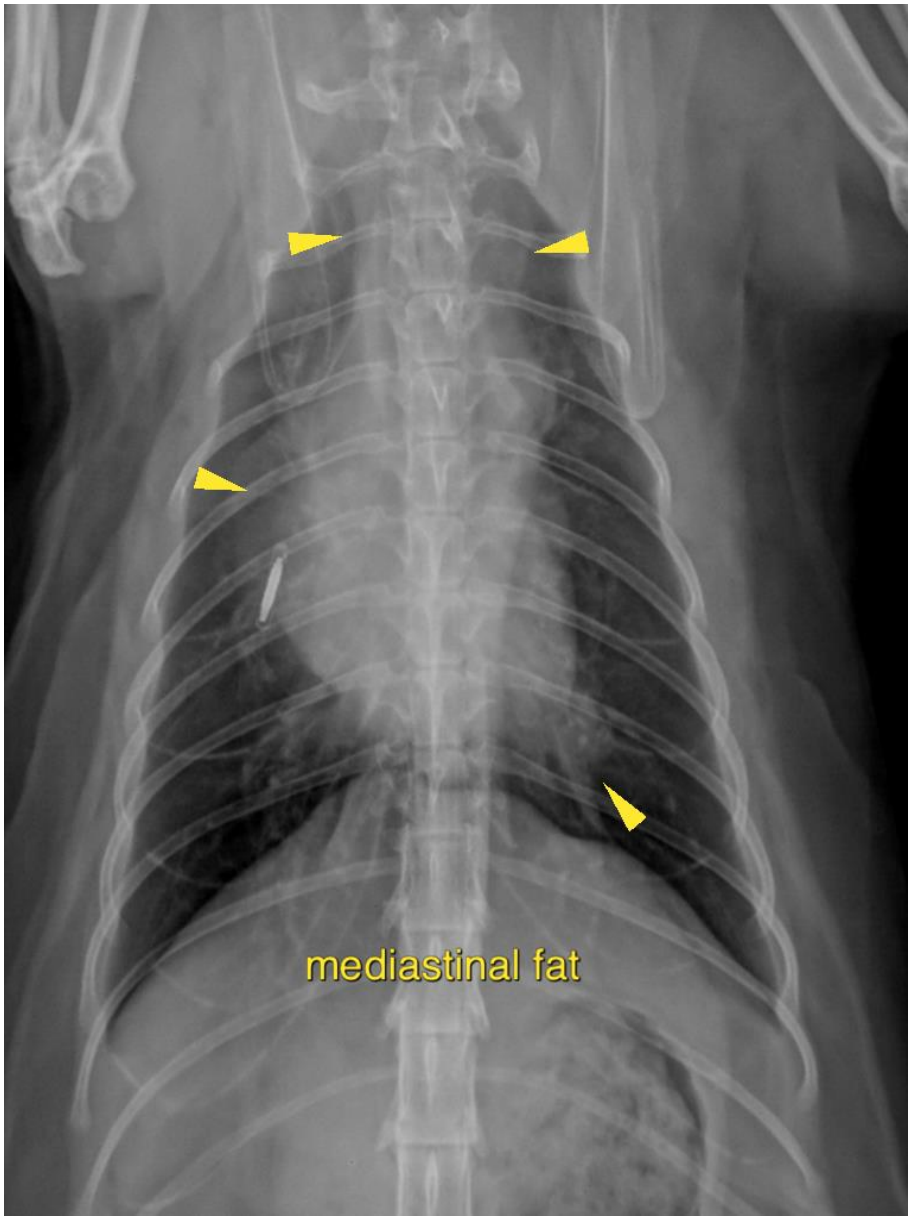

SonoPath Teleradiology

EDUCATIONAL TELECONSULTATION SERVICES™

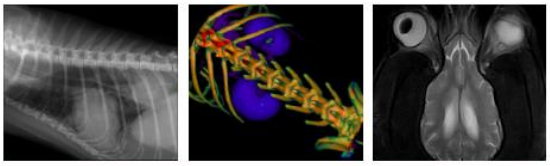

SonoPath.com
1-800-838-4268 info@sonopath.com

PATIENT

Gizmo Amato

SPECIES

Feline

BREED

DSH

SEX

SF

AGE

15 Years

INTERPRETED BY

Sebastian Schaub, DVM
Dr. med. vet. DipECVDI

HOSPITAL NAME

Long Valley Animal Hospital

REFERRING VET

Dr. Stephanie Welch

INVOICE

54265

DATE

9-26-22

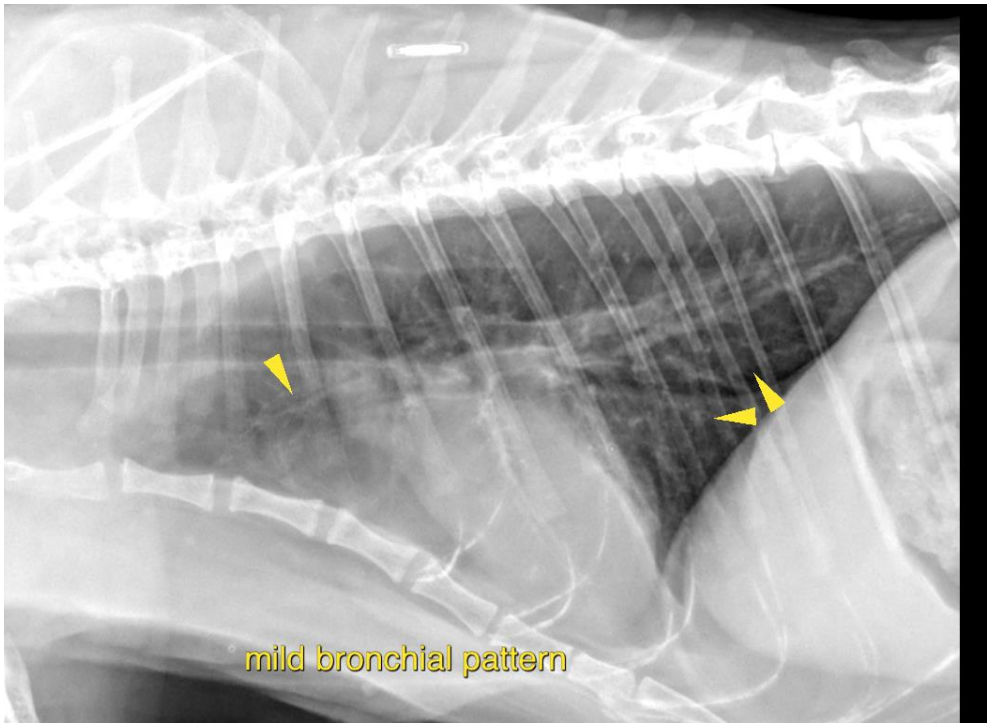

The information and recommendations provided are based on the images presented by the referring veterinarian/sonographer. No evaluation can be communicated regarding pathology that was not visible in the image/video clips provided.

Thank you for this referral. If the clinical or image interpretation does not parallel your findings or if I can be of any further assistance please contact me.

Sebastian Schaub, Sebastian Schaub, DVM, Dr. med. vet. DipECVDI
sebast.schaub@gmail.com