



PATIENT PRESENTING CLINICAL SIGNS

Arlo Moore Swelling rostral maxilla. Looking for DfDx for maxilla and also met check.
Abnormal PE/Chem/CBC/UA Results: NSF.

SPECIES COMPUTED TOMOGRAPHY OF THE SKULL & THORAX

Canine A high resolution plain CT study of the skull and a post-contrast CT study of the thorax are provided for review.

BREED COMPUTED TOMOGRAPHIC FINDINGS

Golden Retriever Skull
Level with triadan 101 to 104 and 201, the incisor part of the right maxillary bone presents permeative osteolytic lesions and immature periosteal new bone formation with an associated ill-defined soft tissue component/mass, causing dorsal deviation of the nasal planum.

SEX
MN The nasal cavity presents the expected aerated spaces between thin & even conchae and turbinates with smooth mucosal lining.

AGE
7 Years Both temporomandibular joints present congruent joint spaces with even subchondral bone surfaces and are considered within normal limits.

Both tympanic bullae are aerated, the mucosal lining is not seen, the bony wall is smooth and thin. The external ear canals are within normal limits.

INTERPRETED BY
Sebastian Schaub, DVM
Dr. med. vet. DipECVDI The submandibular nodes are small and elongated with a normal short-to-long-axis-ratio is < 0.5, the attenuation pattern is uniform.

Thorax
The bony and surrounding soft tissue structures are within normal limits.

HOSPITAL NAME
Animal Health Care
Denver The sternal, cranial mediastinal and tracheobronchial lymph nodes are small elongated with a normal short-to-long-axis-ratio is < 0.5, the attenuation is uniform and considered within normal limits.

REFERRING VET
Cathryn Sayer The bronchial tree presents with regular branching and tapers uniformly towards the periphery as expected, the bronchial walls are thin and smooth. The bronchus-to-artery ratio is within normal limits.

The volume of the right lung lobes is moderately decreased, the parenchyma of the right lung lobes presents multiple regions of compression atelectasis. The lung parenchyma presents the expected architecture and attenuation behavior.

INVOICE
54252 Small incidental gas pockets are seen within the esophageal lumen, there is no evidence of abnormal dilation.

COMPUTED TOMOGRAPHIC DIAGNOSIS

- DATE**
9-25-22
- Polyostotic aggressive osteolytic lesion incisor part maxillary bone bilaterally, R>>L, with associated soft tissue component
 - No evidence of pulmonary metastatic disease – compression atelectasis right lung lobes due to general anesthesia



PATIENT

Arlo Moore

SPECIES

Canine

BREED

Golden Retriever

SEX

MN

AGE

7 Years

INTERPRETED BY

Sebastian Schaub, DVM
Dr. med. vet. DipECVDI

HOSPITAL NAME

Animal Health Care
Denver

REFERRING VET

Cathryn Sayer

INVOICE

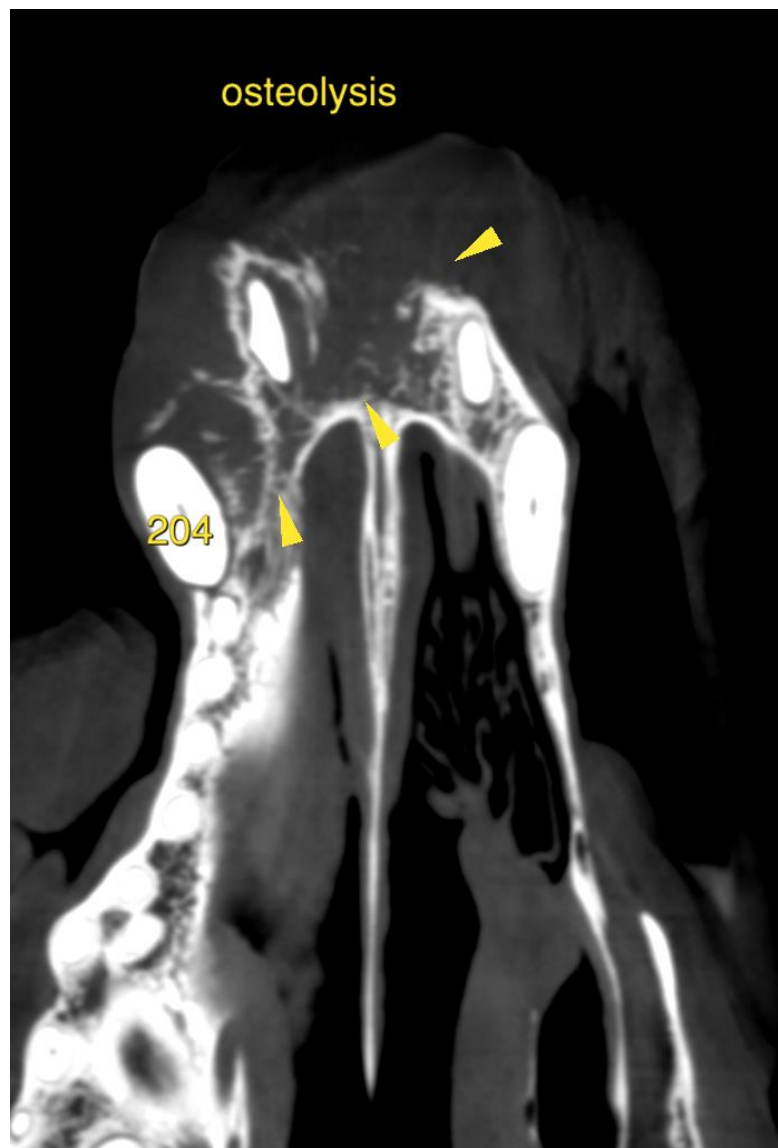54252

DATE

9-25-22

INTERPRETATION OF THE FINDINGS & FURTHER RECOMMENDATIONS

The findings are consistent with neoplastic disease of the rostral maxilla, R>>L with secondary osteolysis of the maxillary bone. Potentials include primary soft tissue neoplasm – such as fibrosarcoma, melanoma, squamous cell carcinoma – or primary tumor of bone (e.g. osteosarcoma, chondrosarcoma). Recommend FNA sampling ± biopsy for further definition. The margins cannot be defined in the plain CT study, however the chances of radiation therapy or surgical management can be discussed with oncologist & surgeon.





PATIENT

Arlo Moore

SPECIES

Canine

BREED

Golden Retriever

SEX

MN

AGE

7 Years

INTERPRETED BY

Sebastian Schaub, DVM
Dr. med. vet. DipECVDI

HOSPITAL NAME

Animal Health Care
Denver

REFERRING VET

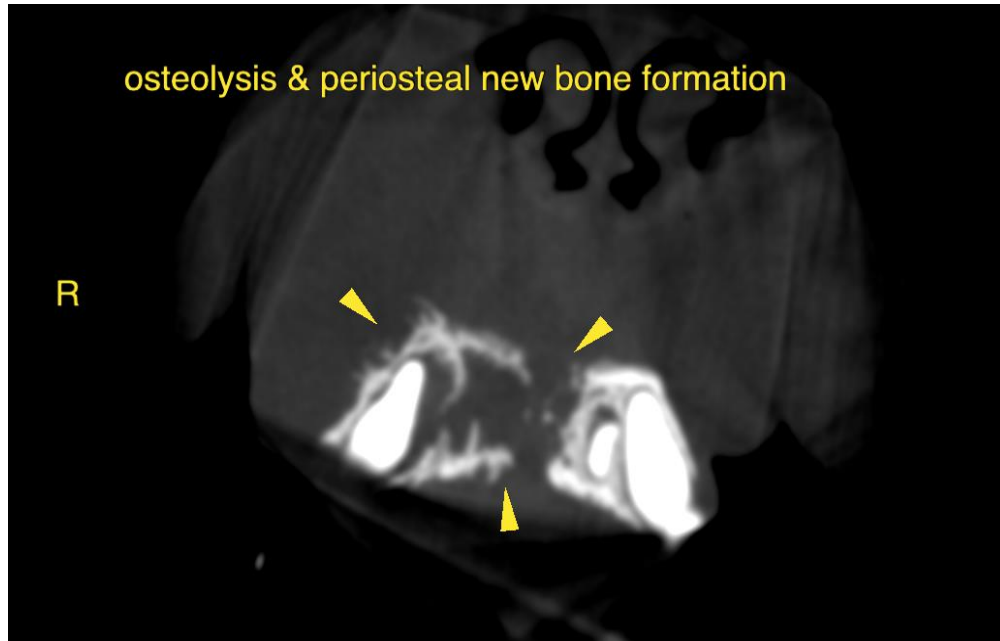
Cathryn Sayer

INVOICE

54252

DATE

9-25-22



The information and recommendations provided are based on the images presented by the referring veterinarian/sonographer. No evaluation can be communicated regarding pathology that was not visible in the image/video clips provided.

Thank you for this referral. If the clinical or image interpretation does not parallel your findings or if I can be of any further assistance please contact me.

Sebastian Schaub, Sebastian Schaub, DVM, Dr. med. vet. DipECVDI
sebast.schaub@gmail.com