



PATIENT PRESENTING CLINICAL SIGNS

Lila Phillipe History: vomiting for 2 days
 Abnormal PE/Chem/CBC/UA Results: blood work is unremarkable

SPECIES RADIOGRAPHIC STUDY OF THE ABDOMEN

Canine Radiographs of the abdomen in three imaging planes are provided for review.

BREED RADIOGRAPHIC FINDINGS

Cavalier King Charles Spaniel The surrounding bony structures are within normal limits.
 No abnormalities of the extraabdominal soft tissues are noted. The abdominal wall is smooth and thin. The serosal detail is maintained throughout the peritoneal and retroperitoneal space.

SEX The liver is appropriate in position, size and presents uniform opacity.

Spayed Female The splenic head is in the anticipated position and within normal limits for size and opacity. The splenic body and tail are considered normal for position, size, shape and opacity.

AGE Both kidneys are seen and present with normal size, shape, delineation and opacity. The urinary bladder is in its anticipated position. No radiopaque calculi are noted throughout the upper and lower urinary tract.

2 Years

The stomach is in its anticipated position and is empty.

INTERPRETED BY

Sebastian Schaub,
 DVM Dr. med. vet.
 DipECVDI

The small intestinal loops are of even diameter and non-dilated, a small amount of gas is seen within the small intestinal loops and considered within normal limits.

The colon is seen in the expected position and contains a mild amount of gas and fecal material.

HOSPITAL NAME RADIOGRAPHIC DIAGNOSIS

St. Catharine's AH • Empty stomach

REFERRING VET INTERPRETATION OF THE FINDINGS & FURTHER RECOMMENDATIONS

Dr. Boctor There is no evidence of radiopaque foreign material or signs for gastrointestinal mechanical obstruction and the presumptive diagnosis is gastritis. Recommend empirical management. If clinical signs are refractory to therapy, follow up radiographs or a complete abdominal ultrasound examination are recommended; in some cases a high ileus can lack classical radiographic signs for mechanical obstruction.

INVOICE

13282

DATE

9/25/21



PATIENT

Lila Phillipe

SPECIES

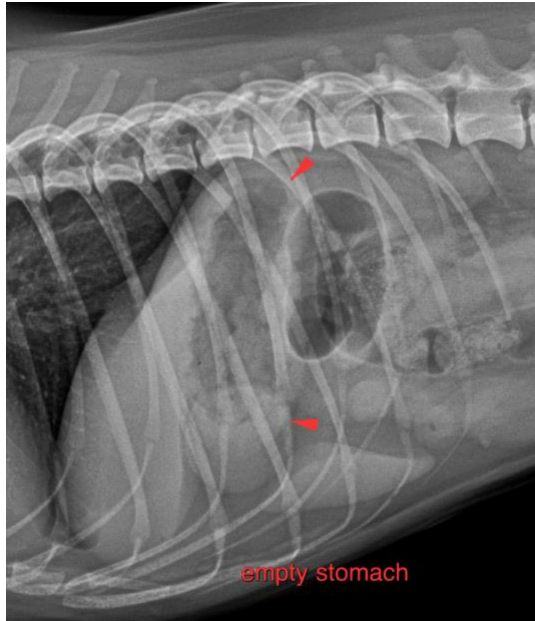
Canine

BREED

Cavalier King Charles
Spaniel

SEX

Spayed Female



AGE

2 Years

The information and recommendations provided are based on the images presented by the referring veterinarian. No evaluation can be communicated regarding pathology that was not visible in the image/video clips provided.

INTERPRETED BY

Thank you for this referral. If the clinical or image interpretation does not parallel your findings or if I can be of any further assistance please contact me.

Sebastian Schaub,
DVM Dr. med. vet.
DipECVDI

Sebastian Schaub, Sebastian Schaub, DVM, Dr. med. vet. DipECVDI
sebast.schaub@gmail.com

HOSPITAL NAME

St. Catharine's AH

REFERRING VET

Dr. Boctor

INVOICE

13282

DATE

9/25/21