



PATIENT PRESENTING CLINICAL SIGNS

Sir Lancelot Tenreiro History: Slipped coming through the door and yelped then was lifting his left front leg up and not using it.

SPECIES Abnormal PE/Chem/CBC/UA Results: LEFT FRONT 3/5 LAME. NOT ABLE TO ISOLATE HEAT, SWELLING OR PAIN IN THE LIMB OR NECK. Showed no sign of pain on palpation.

Canine

RADIOGRAPHIC STUDY OF THE FRONT LIMBS

BREED

A complete set of radiographs of the front limbs is provided for review.

Maltese Mix

RADIOGRAPHIC FINDINGS

SEX

There is breed specific chondrodystrophic conformation of the osseous structures of the front limbs. The shoulder joints present bilaterally are within normal limits.

Neutered Male

The periarticular bones of the left elbow joints present mild osteophyte new bone formation. The osseous margins of the right elbow joint are smooth.

AGE

The carpal joints presents smooth osseous margins and the surrounding soft tissue structures are homogeneous and unremarkable.

12 Years 3 Months

RADIOGRAPHIC DIAGNOSIS

INTERPRETED BY

- Mild degenerative osteoarthritis left elbow joint
- Normal shoulder joints
- Normal carpal joints and front paws

Sebastian Schaub,
DVM Dr. med. vet.
DipECVDI

INTERPRETATION OF THE FINDINGS & FURTHER RECOMMENDATIONS

HOSPITAL NAME

There is evidence of mild degenerative joint disease of the left elbow and acute on chronic insult (e.g. distortion, contusion) by the given trauma is the top differentia. There is no evidence of fracture or signs of swelling. Recommend a clinical trial with NSAIDs and rest.

Elizabeth AH

REFERRING VET

Dr. Leon Anderson

INVOICE

13279

DATE

9/24/21



PATIENT

Sir Lancelot Tenreiro

SPECIES

Canine

BREED

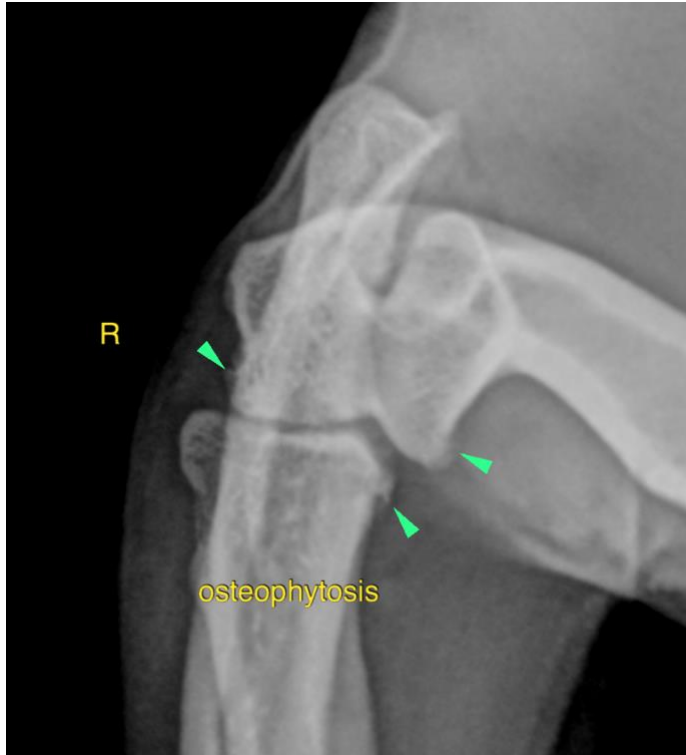
Maltese Mix

SEX

Neutered Male

AGE

12 Years 3 Months



INTERPRETED BY

Sebastian Schaub,
DVM Dr. med. vet.
DipECVDI

The information and recommendations provided are based on the images presented by the referring veterinarian. No evaluation can be communicated regarding pathology that was not visible in the image/video clips provided.

Thank you for this referral. If the clinical or image interpretation does not parallel your findings or if I can be of any further assistance please contact me.

HOSPITAL NAME

Elizabeth AH

Sebastian Schaub, Sebastian Schaub, DVM, Dr. med. vet. DipECVDI
sebast.schaub@gmail.com

REFERRING VET

Dr. Leon Anderson

INVOICE

13279

DATE

9/24/21