



PATIENT PRESENTING CLINICAL SIGNS

PATIENT Harley Webb
HISTORY: Patient in for recheck of lameness/limping. He walks absolutely normally however has a very obvious limp when climbing up the stairs. I (Dr Pala) saw cat for similar presenting complaint on 24th August 2021. O had declined X rays at the time and elected to wait and see if limping resolves just in case it is a soft tissue injury. The limping has NOT resolved, not better and seems to be getting worse.

SPECIES Feline
BREED DSH
SEX Neutered Male
AGE 1 Year 5 Months
INTERPRETED BY Sebastian Schaub, DVM Dr. med. vet. DipECVDI
HOSPITAL NAME River Valley VWC
REFERRING VET Devashree Pala

Cat has never been "a graceful cat" and misses the counter etc when jumping quite often. Cat was adopted when he was 6 months old and found in a really badly injured state when he was found. O is unsure if the cat actually had any muskuloskeletal injuries. Vet care was recieved but O unsure what exactly. Everything else is fine.E/D well, no C/D/V/S. Good energy and mentation. BM/urination normal. Able to posture to urinate/defacate.

RADIOGRAPHIC STUDY OF THE PELVIS

A laterolaterale and ventrodorsal projection of the pelvis are provided for review.

RADIOGRAPHIC FINDINGS

The VD view is mildly rotated. The osseous and surrounding soft tissue structures of the pelvis are within normal limits. The acetabular groove bilaterally is mildly shallow, the joint space of the coxofemoral joints are congruent.

RADIOGRAPHIC DIAGNOSIS

- Mild shallow acetabula

INTERPRETATION OF THE FINDINGS & FURTHER RECOMMENDATIONS

The current radiographic study presents no specific abnormalities. Although the acetabular groove is mildly shallow the clinical relevance of this finding is questionable. The appreciated asymmetry of the depth of the acetabular is due to rotation of the pelvis. Rule out pathology of the distal aspects of the hind limbs as well, such as patellar luxation.

INVOICE

13277

DATE

9/24/21



PATIENT

Harley Webb

SPECIES

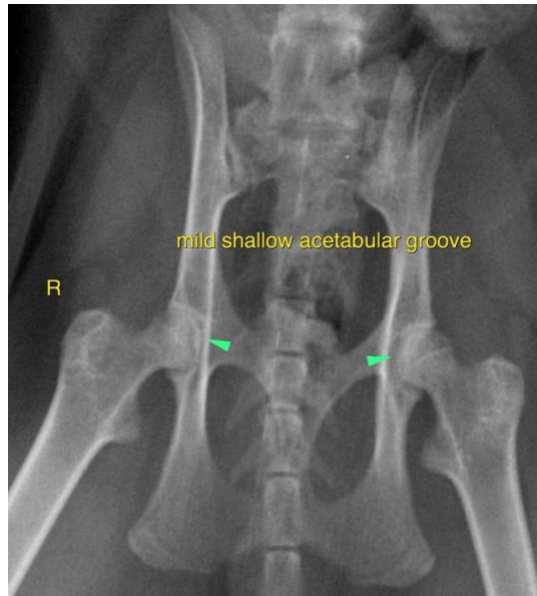
Feline

BREED

DSH

SEX

Neutered Male



AGE

1 Year 5 Months

The information and recommendations provided are based on the images presented by the referring veterinarian. No evaluation can be communicated regarding pathology that was not visible in the image/video clips provided.

INTERPRETED BY

Sebastian Schaub,
DVM Dr. med. vet.
DipECVDI

Thank you for this referral. If the clinical or image interpretation does not parallel your findings or if I can be of any further assistance please contact me.

Sebastian Schaub, Sebastian Schaub, DVM, Dr. med. vet. DipECVDI
sebast.schaub@gmail.com

HOSPITAL NAME

River Valley VWC

REFERRING VET

Devashree Pala

INVOICE

13277

DATE

9/24/21