



PATIENT PRESENTING CLINICAL SIGNS

Frosty Rustad History: Vomiting, diarrhea, lethargy, 10% weight loss in 3 weeks.
Abnormal PE/Chem/CBC/UA Results: painful abdomen

SPECIES RADIOGRAPHIC STUDY OF THE ABDOMEN

Canine A complete set of radiographs of the abdomen is provided for review.

RADIOGRAPHIC FINDINGS

BREED

Husky The surrounding bony structures are within normal limits.

SEX

No abnormalities of the extraabdominal soft tissues are noted. The abdominal wall is smooth and thin. The serosal detail is maintained throughout the peritoneal and retroperitoneal space.

Neutered Male

The splenic head is in the anticipated position and within normal limits for size and opacity. The splenic body and tail are considered normal for position, size, shape and opacity.

AGE

1 Year

Both kidneys are seen and present with normal size, shape, delineation and opacity. The urinary bladder is in its anticipated position. No radiopaque calculi are noted throughout the upper and lower urinary tract.

INTERPRETED BY

Sebastian Schaub,
DVM Dr. med. vet.
DipECVDI

The stomach is partially cropped by the collimation and contains a mild to moderate amount of foamy material and fluid. The small intestinal loops are generalized mildly distended by gas and foamy material and appears tubular.

The colon contains a moderate amount of gas and mild amount of unformed fecal material.

RADIOGRAPHIC DIAGNOSIS

HOSPITAL NAME

Pinebrook AH

- Mild to moderate fluid and gas distension of the stomach
- Mild ingesta pattern and moderate gas pattern of the small intestinal tract
- Overall empty colon

REFERRING VET

Dr. Britt Dubil

INTERPRETATION OF THE FINDINGS & FURTHER RECOMMENDATIONS

The radiographic study is suggestive for underlying gastroenteritis with gastric emptying disorder and mild adynamic intestinal tract. Potentials include dysbacteriosis, food intolerance or parasitic infection. Recommend a fecal exam to check for parasitic infection (e.g. Giardia) and empirical management for suspected gastroenteritis. If clinical signs are refractory to therapy complementing workup by complete blood work and an abdominal ultrasound examination is recommended.

INVOICE

13280

DATE

9/24/21



PATIENT

Frosty Rustad

SPECIES

Canine

BREED

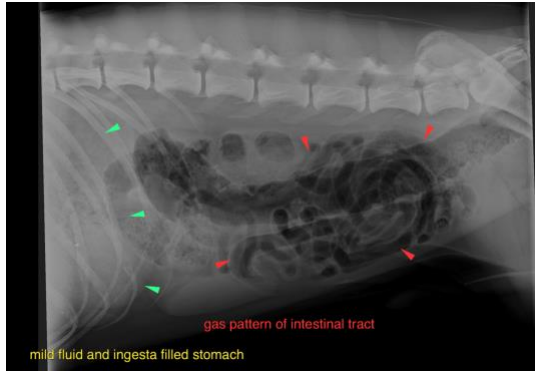
Husky

SEX

Neutered Male

AGE

1 Year



The information and recommendations provided are based on the images presented by the referring veterinarian. No evaluation can be communicated regarding pathology that was not visible in the image/video clips provided.

Thank you for this referral. If the clinical or image interpretation does not parallel your findings or if I can be of any further assistance please contact me.

Sebastian Schaub, Sebastian Schaub, DVM, Dr. med. vet. DipECVDI
sebast.schaub@gmail.com

INTERPRETED BY

Sebastian Schaub,
DVM Dr. med. vet.
DipECVDI

HOSPITAL NAME

Pinebrook AH

REFERRING VET

Dr. Britt Dubil

INVOICE

13280

DATE

9/24/21