



PATIENT

Ollie Bollman

PRESENTING CLINICAL SIGNS

HX - VOMITING/DIARRHEA FOR 2 DAYS. DEHYDRATION. BW - UNREMARKABLE.

SPECIES

Canine

RADIOGRAPHIC STUDY OF THE ABDOMEN

Radiographs of the abdomen in three imaging planes are provided for review.

BREED

Shih Tzu Mix

RADIOGRAPHIC FINDINGS

The surrounding bony structures are within normal limits.

No abnormalities of the extraabdominal soft tissues are noted. The abdominal wall is smooth and thin.

SEX

Male Neuter

The serosal detail is maintained throughout the peritoneal and retroperitoneal space.

The hepatic volume is mild to moderately increased, the caudoventral hepatic margins are protruding caudally beyond the costal arch and are rounded.

AGE

9 Years

The splenic head is in the anticipated position and within normal limits for size and opacity. The splenic body and tail are considered normal for position, size, shape and opacity.

Both kidneys are seen and present with normal size, shape, delineation and opacity. The urinary bladder is in its anticipated position. No radiopaque calculi are noted throughout the upper and lower urinary tract.

INTERPRETED BY

Sebastian Schaub, DVM
Dr. med. vet. DipECVDI

The stomach is in its anticipated position and is empty.

The small intestinal loops are of even diameter and non-dilated, a small amount of gas is seen within the small intestinal loops and considered within normal limits.

The colon is seen in the expected position and is empty but a mild to moderate amount of gas.

HOSPITAL NAME

St. Catherine's Animal
Hospital

RADIOGRAPHIC DIAGNOSIS

- Empty gastrointestinal tract
- Mild hepatomegaly

REFERRING VET

Dr. Boctor

INTERPRETATION OF THE FINDINGS & FURTHER RECOMMENDATIONS

The empty gastrointestinal tract in combination with the presenting clinical signs is most consistent with gastroenteritis. There is no evidence of radiopaque foreign material or signs for gastrointestinal mechanical obstruction. If not done so yet, complementing blood work by cpl can be used to rule out underlying pancreatitis.

INVOICE

54230

DATE

9-23-22



PATIENT

Ollie Bollman

SPECIES

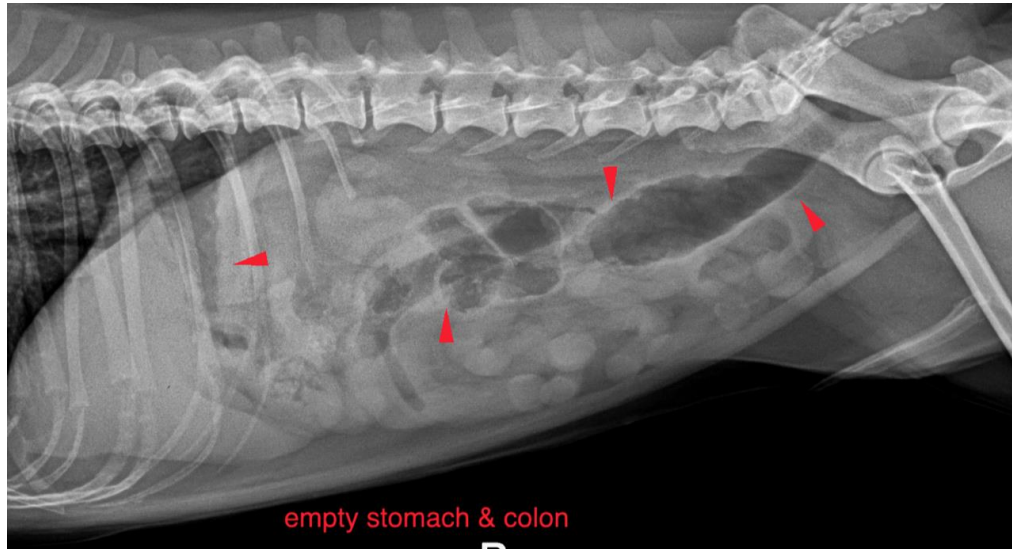
Canine

BREED

Shih Tzu Mix

SEX

Male Neuter



AGE

9 Years

INTERPRETED BY

Sebastian Schaub, DVM
Dr. med. vet. DipECVDI

HOSPITAL NAME

St. Catherine's Animal
Hospital

REFERRING VET

Dr. Boctor

INVOICE

54230

DATE

9-23-22

The information and recommendations provided are based on the images presented by the referring veterinarian/sonographer. No evaluation can be communicated regarding pathology that was not visible in the image/video clips provided.

Thank you for this referral. If the clinical or image interpretation does not parallel your findings or if I can be of any further assistance please contact me.

Sebastian Schaub, Sebastian Schaub, DVM, Dr. med. vet. DipECVDI
sebast.schaub@gmail.com