

**PATIENT**

Lucia Lepore

PRESENTING CLINICAL SIGNS

Having trouble getting up with hind legs, stiff ; Xrays: R/O hip dysplasia. Current Meds: Carprofen 75 mgs 1 BID

Abnormal PE/Chem/CBC/UA Results: Vet screen and CBC all WNL, HWT negative, Ehrlichia. Ana, Lyme all negative. Urinalysis: Not done

SPECIES

Canine

RADIOGRAPHIC STUDY OF THE PELVIS AND STIFLE JOINTS

Radiographs of the pelvis in a ventrodorsal projection and the stifle joints in two orthogonal imaging planes are provided for review.

BREED

Doberman Pincher

RADIOGRAPHIC FINDINGS

The osseous and surrounding soft tissue structures of the pelvis are within normal limits. Both coxofemoral joints present smooth osseous margins and congruent joint spaces.

SEX

Female

The periarticular bones of the left stifle joint present mild osteophyte new bone formation. The osseous margins of the right stifle joint are smooth. Both stifle joints present a moderate intracapsular soft tissue swelling, partially effacing the infrapatellar fat pad cranially and distorting the fascial plane caudally.

AGE

13 Months

- Mild degenerative osteoarthritis left stifle joint
- Moderate articular swelling stifle joints bilaterally
- Normal pelvis/coxofemoral joints

INTERPRETED BY

Sebastian Schaub, DVM
Dr. med. vet. DipECVDI

INTERPRETATION OF THE FINDINGS & FURTHER RECOMMENDATIONS

The radiographic study is consistent with joint effusion of both stifle joints and mild degenerative osteoarthritis of the left stifle joint. The most-likely underlying cause is (partial) rupture of the cranial cruciate ligament with or without meniscal disease. A synovial tap can be used to rule out underlying immune mediated or less likely infectious arthritis.

A positive drawer sign or tibial compression test under general anesthesia can be used to confirm the diagnosis of pathology of the cranial cruciate ligament.

HOSPITAL NAME

Byram Animal
Hospital

REFERRING VET

Dr. Maria Cruz

INVOICE

54231

DATE

9-23-22



PATIENT

Lucia Lepore

SPECIES

Canine

BREED

Doberman Pincher

SEX

Female

AGE

13 Months

INTERPRETED BY

Sebastian Schaub, DVM
Dr. med. vet. DipECVDI

HOSPITAL NAME

Byram Animal
Hospital

REFERRING VET

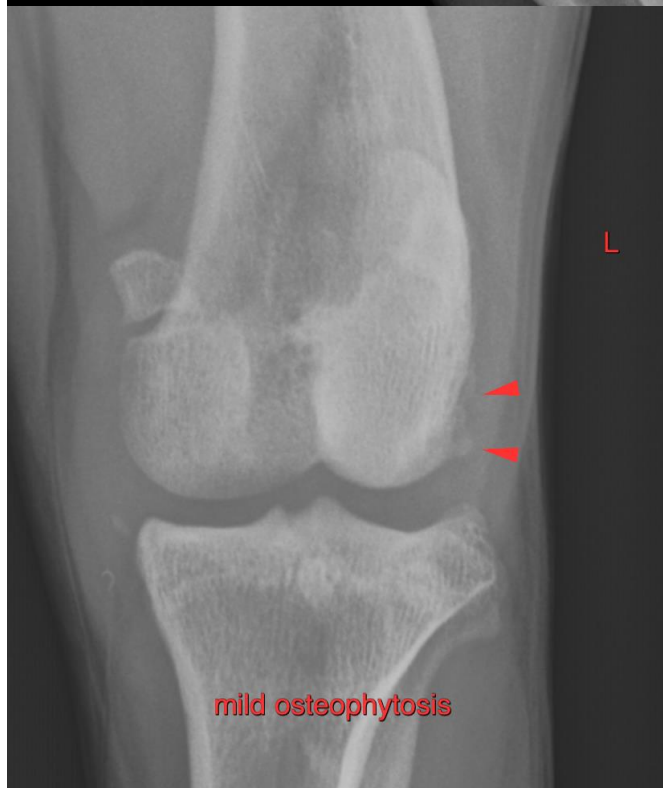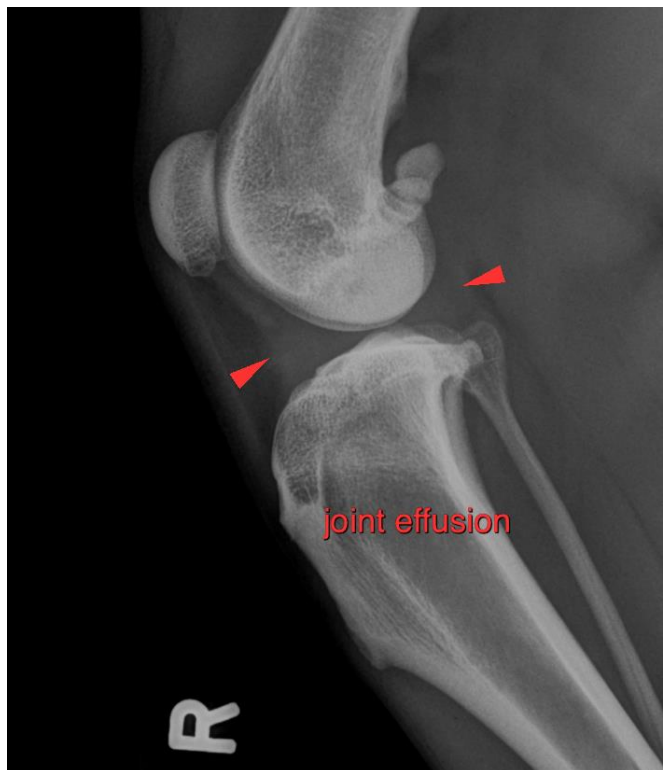
Dr. Maria Cruz

INVOICE

54231

DATE

9-23-22





PATIENT

Lucia Lepore

SPECIES

Canine

BREED

Doberman Pincher

SEX

Female

AGE

13 Months

INTERPRETED BY

Sebastian Schaub, DVM
Dr. med. vet. DipECVDI

HOSPITAL NAME

Byram Animal
Hospital

REFERRING VET

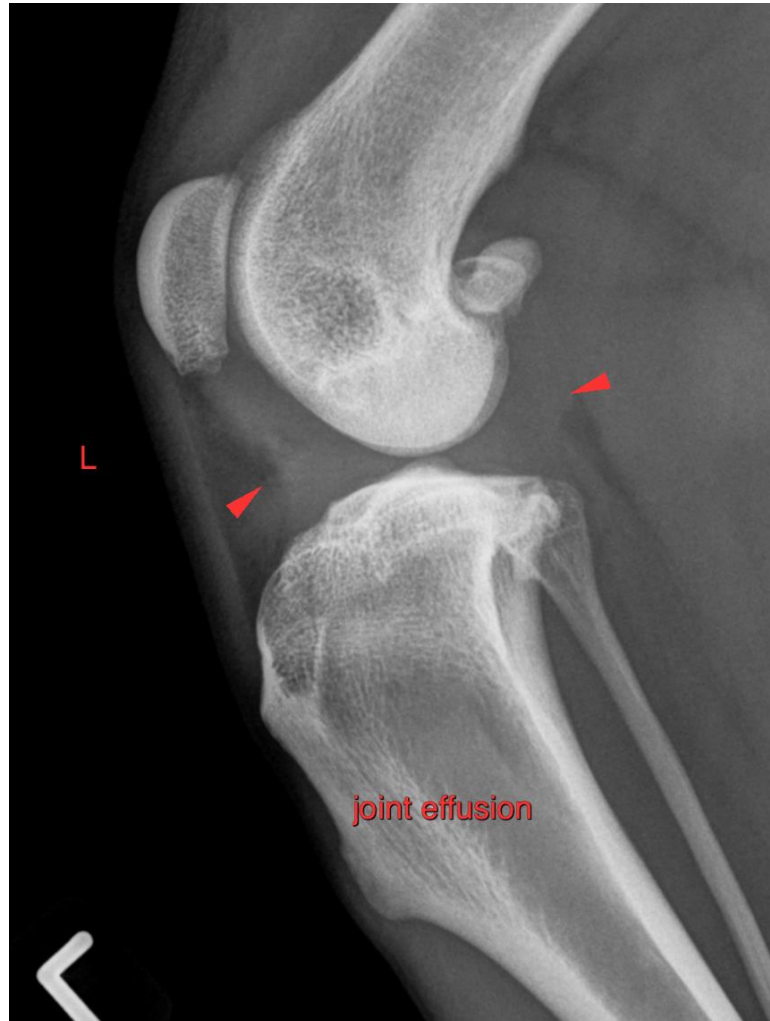Dr. Maria Cruz

INVOICE

54231

DATE

9-23-22



The information and recommendations provided are based on the images presented by the referring veterinarian/sonographer. No evaluation can be communicated regarding pathology that was not visible in the image/video clips provided.

Thank you for this referral. If the clinical or image interpretation does not parallel your findings or if I can be of any further assistance please contact me.

Sebastian Schaub, Sebastian Schaub, DVM, Dr. med. vet. DipECVDI
sebast.schaub@gmail.com