



**PATIENT PRESENTING CLINICAL SIGNS**

Henleigh McGuire History: Periodontitis, Severe Periodontal disease (PD4) with Hx of left periorbital abscessation resulting in exophthalmos and corneal ulceration of the left eye currently managed with 15 mg Clindamycin BID, and Moxifloxacin eye drops TID.

**SPECIES COMPUTED TOMOGRAPHIC STUDY OF THE SKULL**

Canine A high resolution pre- and post-contrast CT study of the skull is provided for review.

**BREED COMPUTED TOMOGRAPHIC FINDINGS**

Maltipoo Triadan 106, 110, 206, 210, 305, 306, 311, 402, 405, 406 and 411 are absent. Advanced abrasion of the crowns of the canine teeth is appreciated. Triadan 109, 209, 310 and 410 present a moderate widening of the periodontal space. Triadan 101 and 102 present a periapical widening of the periodontal space with perforation of the nasal cavity. Periapical widening of the periodontal space of triadan 304 is appreciated. The remaining teeth present evidence of mild to moderate periodontal disease. Advanced dental resorption of triadan 308 is noted.

**SEX**

Spayed Female

**AGE**

12 Years

The nasal cavity presents the expected aerated spaces between thin & even conchae and turbinates with smooth mucosal lining.

Both temporomandibular joints present congruent joint spaces with even subchondral bone surfaces and are considered within normal limits.

**INTERPRETED BY**

Sebastian Schaub, DVM  
Dr. med. vet. DipECVDI

Both tympanic bullae are aerated, the mucosal lining is not seen, the bony wall is smooth and thin. The external ear canals are within normal limits.

**HOSPITAL NAME**

Mobile Pet Imaging

The brain presents no deviation from normal anatomy and symmetry. The brain parenchyma is homogeneous and within normal limits for attenuation and distribution of contrast enhancement. The ventricular system is non-dilated and symmetric.

The submandibular and medial retropharyngeal lymph nodes are small and elongated with a normal short-to-long-axis-ratio is < 0.5, the attenuation and contrast enhancement pattern is uniform.

**REFERRING VET**

Meaux

**COMPUTED TOMOGRAPHIC DIAGNOSIS**

- Periodontal abscess formation 101 and 102 with oronasal fistula formation
- Periodontal granuloma 304
- Periodontal disease 109, 209, 310 and 410
- Generalized mild periodontal disease of the remaining teeth
- Abrasion of the crowns of triadan 104, 204, 304 and 404
- Multiple absent teeth, see above

**INVOICE**

17450

**DATE**

9/23/22

**INTERPRETATION OF THE FINDINGS & FURTHER RECOMMENDATIONS**



**PATIENT** A complete dental workup with extraction of the affected teeth is considered beneficial.

Henleigh McGuire

**SPECIES**

Canine

**BREED**

Maltipoo

**SEX**

Spayed Female

**AGE**

12 Years

**INTERPRETED BY**

Sebastian Schaub, DVM  
Dr. med. vet. DipECVDI

**HOSPITAL NAME**

Mobile Pet Imaging

**REFERRING VET**

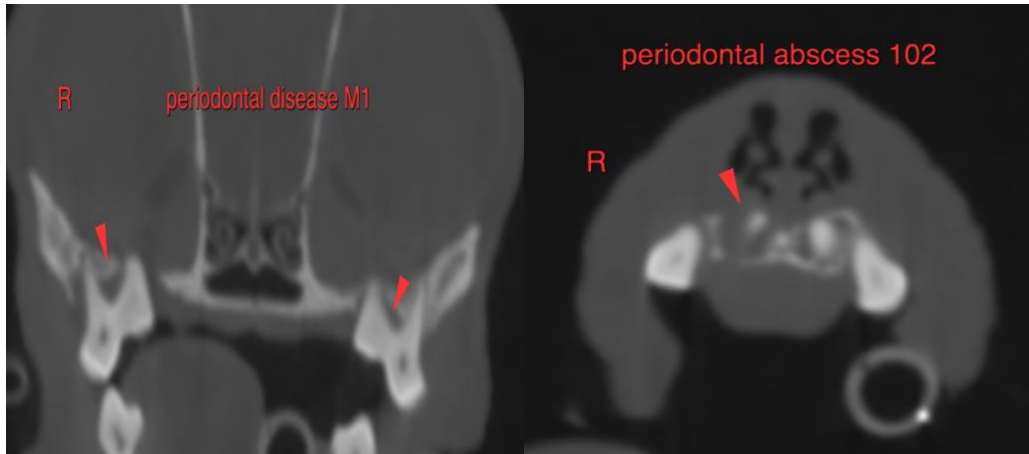
Meaux

**INVOICE**

17450

**DATE**

9/23/22



**The information and recommendations provided are based on the images presented by the referring veterinarian/sonographer. No evaluation can be communicated regarding pathology that was not visible in the image/video clips provided.**

Thank you for this referral. If the clinical or image interpretation does not parallel your findings or if I can be of any further assistance please contact me.

**Sebastian Schaub**, Sebastian Schaub, DVM, Dr. med. vet. DipECVDI  
sebast.schaub@gmail.com