



**PATIENT PRESENTING CLINICAL SIGNS**

Mia Kanski History: P has intermittent limping on front right leg. Pain response given when manipulated elbows. Abnormal PE/Chem/CBC/UA Results:

**SPECIES COMPUTED TOMOGRAPHIC STUDY OF THE FRONT LIMBS**

Canine A high resolution plain CT study of the elbow joints is provided for review.

**COMPUTED TOMOGRAPHIC FINDINGS**

**BREED** Both elbow joints present smooth osseous margins. The medial coronoid process bilaterally has a homogeneous density with a trabecular osseous pattern. Both elbow joints present a mild incongruity with a very small radio-ulnar step formation <1 mm. The right medial coronoid process shows a diverging faint hypoattenuating line extending from the cranial tip into the medial coronoid process - potential small vascular canals.  
**Mixed**

**SEX**

Spayed Female

**COMPUTED TOMOGRAPHIC DIAGNOSIS**

- Very mild incongruity elbow joints bilaterally

**AGE**

2 Years 11 Months

**INTERPRETATION OF THE FINDINGS & FURTHER RECOMMENDATIONS**

The CT study of the elbow joints presents without specific pathology, the faint lines in the right medial coronoid process can represent small vascular canals there are no computed tomographic signs for fragmentation. If clinical signs support the diagnosis of disease of the medial coronoid process despite negative computed tomography, arthroscopy might be considered as in few cases non-vital cartilage flap can be present.

**INTERPRETED BY**

Sebastian Schaub,  
DVM Dr. med. vet.  
DipECVDI

**HOSPITAL NAME**

State Avenue VC

**REFERRING VET**

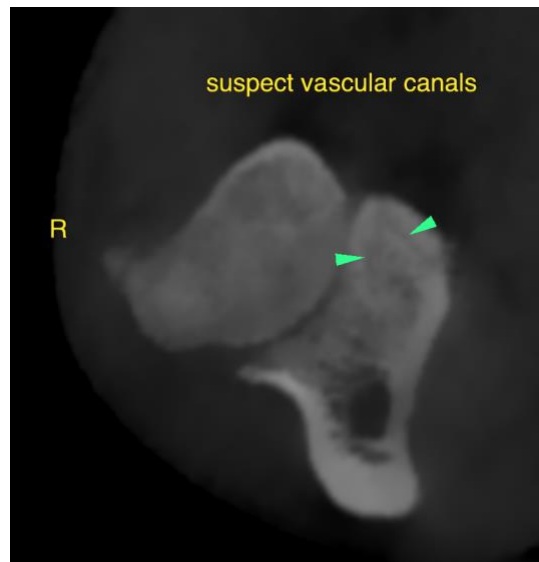
Dr. Raul Casas-Dolz

**INVOICE**

13271

**DATE**

9/23/21



The information and recommendations provided are based on the images presented by the referring



**PATIENT** veterinarian. No evaluation can be communicated regarding pathology that was not visible in the image/video clips provided.

Mia Kanski

Thank you for this referral. If the clinical or image interpretation does not parallel your findings or if I can be of any further assistance please contact me.

**SPECIES**

Canine

**Sebastian Schaub**, Sebastian Schaub, DVM, Dr. med. vet. DipECVDI  
sebast.schaub@gmail.com

**BREED**

Mixed

**SEX**

Spayed Female

**AGE**

2 Years 11 Months

**INTERPRETED BY**

Sebastian Schaub,  
DVM Dr. med. vet.  
DipECVDI

**HOSPITAL NAME**

State Avenue VC

**REFERRING VET**

Dr. Raul Casas-Dolz

**INVOICE**

13271

**DATE**

9/23/21