



**PATIENT PRESENTING CLINICAL SIGNS**

Arthur Cha History: sonopath consult. 9 month old cavapoo with a progressive LH leg lameness x 3 months. no pain elicited. nothing abnormal palpable on PE. under sedation for rads- patella wnl, no drawer sign, and hips palpate ok. I did not see any pathology. dog is BARH. thank you!

**SPECIES** Abnormal PE/Chem/CBC/UA Results:

Canine **RADIOGRAPHIC STUDY OF THE PELVIS AND STIFLE JOINTS**

A complete set of radiographs of the pelvis and stifle joints is provided for review.

**BREED RADIOGRAPHIC FINDINGS**

Cavapoo The growth plates are age related open.

**SEX** The last lumbar vertebra articulates with the right iliosacral joint and presents a transverse process in the left aspect.

Neutered Male

The osseous and surrounding soft tissue structures of the coxofemoral joints are within normal limits.

**AGE** Both stifle joints present smooth osseous margins without evidence of pathological intracapsular swelling.

9 Months

**RADIOGRAPHIC DIAGNOSIS**

**INTERPRETED BY**

- Asymmetric lumbosacral transitional vertebral (Type III)
- Structural normal pelvis and coxofemoral joints
- Normal stifle joints

Sebastian Schaub,  
DVM Dr. med. vet.  
DipECVDI

**HOSPITAL NAME**

**INTERPRETATION OF THE FINDINGS & FURTHER RECOMMENDATIONS**

Tenaflly VC

The radiographic study of the pelvis and stifle joints presents no abnormality, explaining the left hind limb lameness. The clinical relevance of the lumbosacral transitional vertebra is questionable, but may predispose for local discopathy.

**REFERRING VET**

Marcela Salas

If no pain can be elicited and lameness is refractory to empirical therapy, scintigraphy is a potential advanced imaging modality to screen for 'hot-spot' as potential source for the lameness.

**INVOICE**

13266

**DATE**

9/23/21



**PATIENT**

Arthur Cha

**SPECIES**

Canine

**BREED**

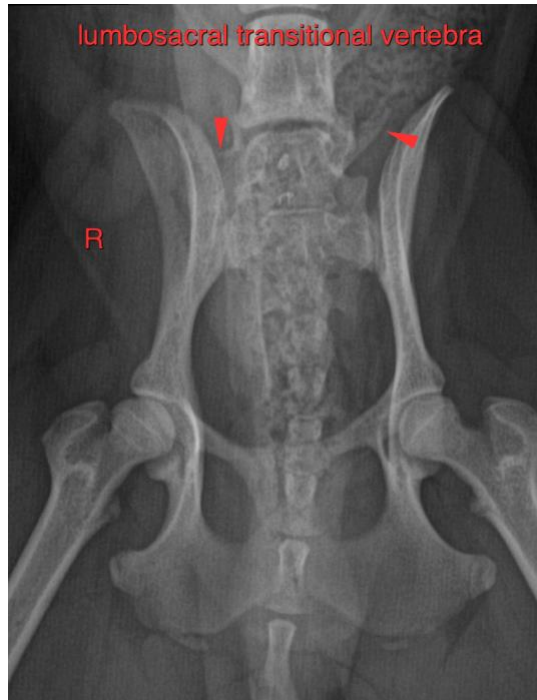
Cavapoo

**SEX**

Neutered Male

**AGE**

9 Months



**INTERPRETED BY**

Sebastian Schaub,  
DVM Dr. med. vet.  
DipECVDI

**The information and recommendations provided are based on the images presented by the referring veterinarian. No evaluation can be communicated regarding pathology that was not visible in the image/video clips provided.**

Thank you for this referral. If the clinical or image interpretation does not parallel your findings or if I can be of any further assistance please contact me.

**HOSPITAL NAME**

Tenaflly VC

**Sebastian Schaub**, Sebastian Schaub, DVM, Dr. med. vet. DipECVDI  
sebast.schaub@gmail.com

**REFERRING VET**

Marcela Salas

**INVOICE**

13266

**DATE**

9/23/21