



PATIENT PRESENTING CLINICAL SIGNS

PATIENT Piper Serlin History: A few days before the end of August patient was playing outside and came up lame acutely RPL, has been limping on and off since, limping continuously last two days, exam done under sedation due to patient being aggressive, mild tibial thrust and stifle thickening, could not assess for pain because patient sedated, was not limping when walked into hospital today

SPECIES

Canine Abnormal PE/Chem/CBC/UA Results:

RADIOGRAPHIC STUDY OF THE STIFLE JOINTS

BREED

Radiographs of the right stifle joint in orthogonal imaging planes are provided for review.

American
Staffordshire Terrier

RADIOGRAPHIC FINDINGS

The volume of the soft tissue shadow of the right hind limb is moderately decreased. The right stifle joint presents a moderate intracapsular soft tissue swelling distorting the infrapatellar fat pad and displacing the fascial plane caudally. The periarticular bones of the right stifle joint present moderate osteophyte new bone formation. The right tibial plateau presents mild caudal osseous elongation.

SEX

Spayed Female

RADIOGRAPHIC DIAGNOSIS

AGE

3 Years 10 Months

- Moderate degenerative osteoarthritis right stifle joint
- Moderate articular swelling of the right stifle joint
- Mild caudal elongation of right tibial plateau
- Disuse atrophy right thigh musculature

INTERPRETED BY

Sebastian Schaub,
DVM Dr. med. vet.
DipECVDI

INTERPRETATION OF THE FINDINGS & FURTHER RECOMMENDATIONS

The radiographic study is consistent with right sided chronic degenerative osteoarthritis with concomitant joint effusion of the stifle joint. The most-likely underlying cause is (partial) rupture of the cranial cruciate ligament with or without meniscal disease.

HOSPITAL NAME

Lambs Gap AH

A positive drawer sign or tibial compression test under general anesthesia can be used to confirm the diagnosis and surgical intervention – a correction osteotomy technique would be ideal – would be beneficial.

REFERRING VET

Cynthia Kinney

INVOICE

13265

DATE

9/22/21



PATIENT

Piper Serlin

SPECIES

Canine

BREED

American
Staffordshire Terrier

SEX

Spayed Female

AGE

3 Years 10 Months

INTERPRETED BY

Sebastian Schaub,
DVM Dr. med. vet.
DipECVDI

HOSPITAL NAME

Lambs Gap AH

REFERRING VET

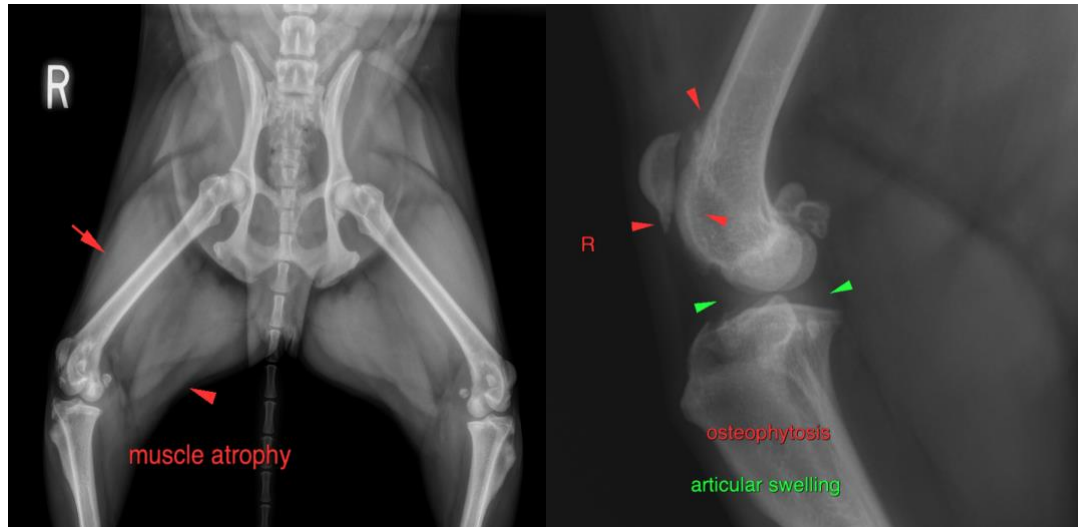
Cynthia Kinney

INVOICE

13265

DATE

9/22/21



The information and recommendations provided are based on the images presented by the referring veterinarian. No evaluation can be communicated regarding pathology that was not visible in the image/video clips provided.

Thank you for this referral. If the clinical or image interpretation does not parallel your findings or if I can be of any further assistance please contact me.

Sebastian Schaub, Sebastian Schaub, DVM, Dr. med. vet. DipECVDI
sebast.schaub@gmail.com