



**PATIENT**

Samantha Fox  
Gastaldi

**PRESENTING CLINICAL SIGNS**

Hx of plural effusion mass in thoracic cavity

**COMPUTED TOMOGRAPHY OF THE THORAX AND ABDOMEN**

A high resolution post contrast CT study of the thorax and abdomen is provided for review.

**SPECIES**

Feline

**COMPUTED TOMOGRAPHIC FINDINGS**

Thorax

The bony and surrounding soft tissue structures are within normal limits.

**BREED**

DLH

In the cranioventral mediastinum, an ill-defined heterogeneous contrast enhancing, multilobulated soft tissue mass is visible, measuring 4.7 x 3.6 x 10.5 cm in size. The cranial mediastinal mass is occupying up to the complete width of the thoracic cavity and extending caudally, ventral to the heart up to the level of the diaphragm. The heart is deviated dorsally by the mass effect. The lung lobes are retraced from the ventral thoracic walls due to the widened mediastinum.

**SEX**

FS

A small amount of gravity dependent fluid attenuating material is appreciated in the right pleural cavity.

**AGE**

10 Years

The right lung lobes present multiple regions of compression atelectasis.

Small incidental gas pockets are seen within the esophageal lumen, there is no evidence of abnormal dilation.

**INTERPRETED BY**

Sebastian Schaub, DVM  
Dr. med. vet. DipECVDI

Abdomen

The serosal fat presents normal attenuation behavior. There is no evidence of peritoneal effusion or peritonitis.

**HOSPITAL NAME**

Animal Surgical  
Center

Both kidneys present within normal limits for size, shape and organ architecture. After contrast administration a bilaterally symmetric and uniform nephro- and pyelogram is noted.

The adrenal glands are within normal limits for size, shape and organ architecture.

Both liver and spleen present with normal shape, even surface, uniformly attenuating parenchyma and homogeneous contrast enhancement, unremarkable.

**REFERRING VET**

South Shore Animal  
Hospital

The pancreas is evenly contoured, the pancreatic parenchyma is homogeneous and presents uniform contrast enhancement.

The position, delineation, wall and content of the gastrointestinal tract are considered within normal limits throughout.

**INVOICE**

54199

The bony and surrounding soft tissue structures reveal no abnormalities.

**COMPUTED TOMOGRAPHIC DIAGNOSIS**

- Large cranioventral mediastinal mass, extending caudally up to the level of the diaphragm
- Compression atelectasis ventral aspects of the lung
- Very mild pleural effusion
- Normal abdomen

**DATE**

9-21-22



**PATIENT**

Samantha Fox  
Gastaldi

**INTERPRETATION OF THE FINDINGS & FURTHER RECOMMENDATIONS**

There is a large mediastinal mass extending from the level of the cranial thoracic aperture caudally up to the diaphragm, consistent with neoplastic disease. Differentials include (thymic) lymphosarcoma, thymoma, thymic carcinoma/sarcoma, other. If not done so yet, FNA sampling of the mediastinal mass is recommended and the chances of palliative options – such as chemotherapy or radiation therapy – should be discussed with oncologist.

**SPECIES**

Feline

**BREED**

DLH

**SEX**

FS

**AGE**

10 Years

**INTERPRETED BY**

Sebastian Schaub, DVM  
Dr. med. vet. DipECVDI

**HOSPITAL NAME**

Animal Surgical  
Center

**REFERRING VET**

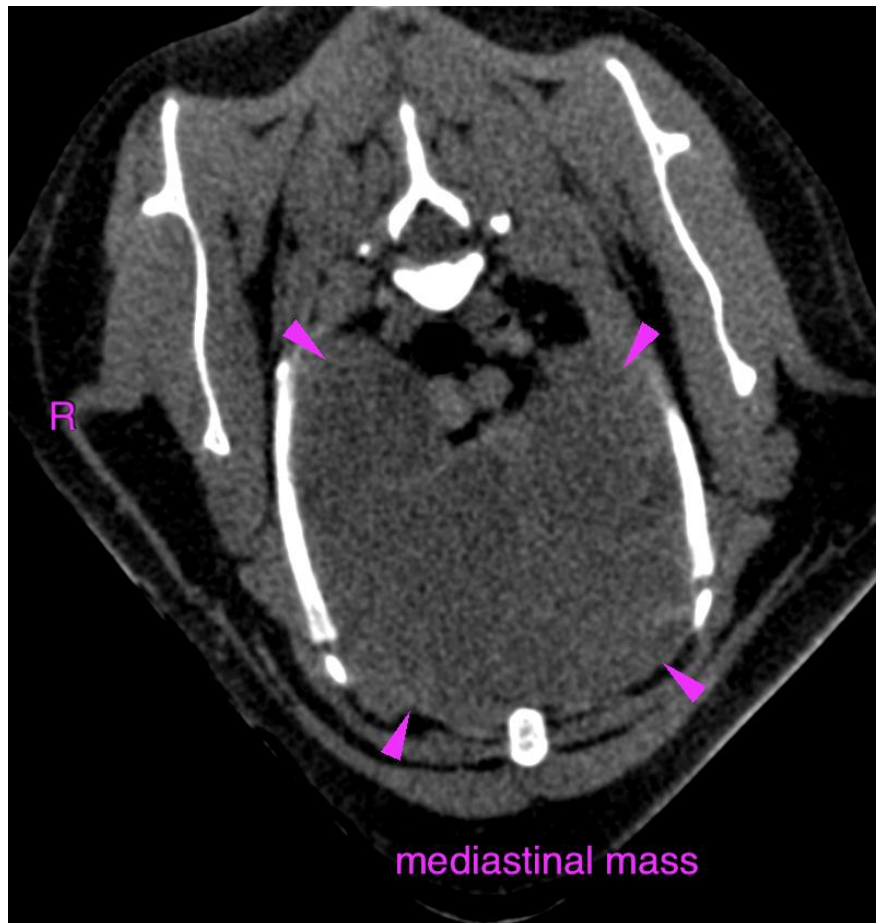
South Shore Animal  
Hospital

**INVOICE**

54199

**DATE**

9-21-22





**PATIENT**

Samantha Fox  
Gastaldi

**SPECIES**

Feline

**BREED**

DLH

**SEX**

FS

**AGE**

10 Years

**INTERPRETED BY**

Sebastian Schaub, DVM  
Dr. med. vet. DipECVDI

**HOSPITAL NAME**

Animal Surgical  
Center

**REFERRING VET**

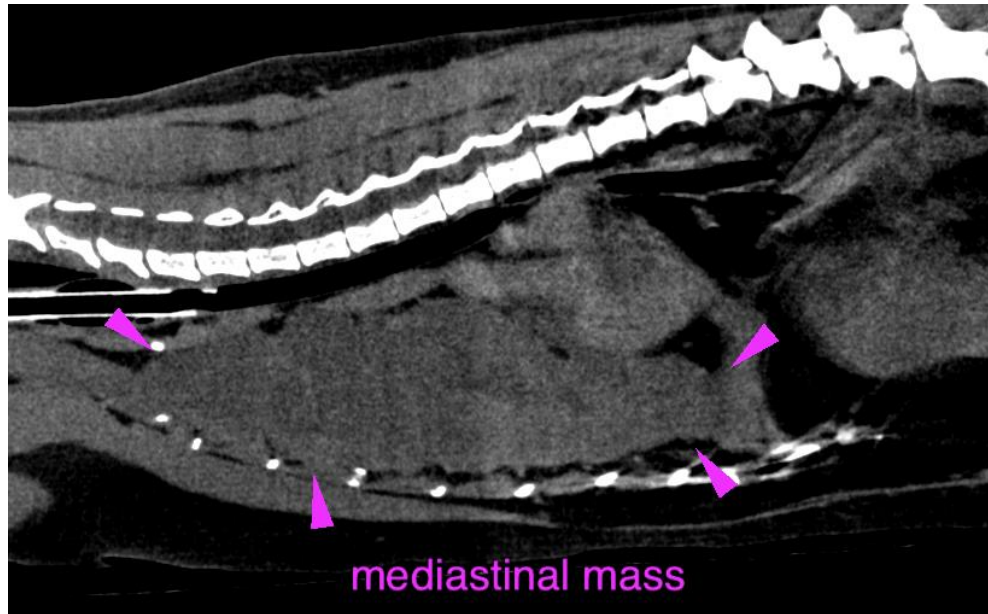
South Shore Animal  
Hospital

**INVOICE**

54199

**DATE**

9-21-22



The information and recommendations provided are based on the images presented by the referring veterinarian/sonographer. No evaluation can be communicated regarding pathology that was not visible in the image/video clips provided.

Thank you for this referral. If the clinical or image interpretation does not parallel your findings or if I can be of any further assistance please contact me.

**Sebastian Schaub**, Sebastian Schaub, DVM, Dr. med. vet. DipECVDI  
sebast.schaub@gmail.com