



**PATIENT**

Rocco Alagna

**PRESENTING CLINICAL SIGNS**

RT FORELIMB LAMENESS ON THE RT SIDE POSSIBLE LT, AS WELL.

**SPECIES**

Canine

**COMPUTED TOMOGRAPHY OF THE NECK & FRONT LIMBS**

A high resolution plain CT study of the neck & front limbs is provided for review.

**BREED**

Bermese Mountain  
Dog

**COMPUTED TOMOGRAPHIC FINDINGS**

The osseous and soft tissue structures of the cervical spine present without abnormalities.

The periarticular bones of both shoulder joints present moderate osteophyte new bone formation and mild exostosis formation in the distal aspect of the bicipital groove of the humerus bilaterally. Along the level of the lateral aspect of the joint capsule of the left stifle joint, small mineralization are appreciated.

**SEX**

MN

Both elbow joints present smooth osseous margins, and no abnormalities of the surrounding soft tissue structures are appreciated.

The osseous and soft tissue structures of the antebrachium, carpal joint and metacarpal region bilaterally are within normal limits.

**AGE**

8 Years

**COMPUTED TOMOGRAPHIC DIAGNOSIS**

- Degenerative osteoarthritis shoulder joints bilaterally with exostosis formation in the bicipital groove of the humerus bilaterally, R>L
- Suspect synovial osteochondromatosis left shoulder joint
- Normal cervical spine
- Normal elbow joints
- Normal antebrachium & carpal joints

**INTERPRETED BY**

Sebastian Schaub, DVM  
Dr. med. vet. DipECVDI

**HOSPITAL NAME**

Animal Surgical  
Center

**INTERPRETATION OF THE FINDINGS & FURTHER RECOMMENDATIONS**

Both shoulder joints present signs of degenerative joint disease, that might be a source for the clinical signs. An ultrasound examination of the shoulder joints would be ideal to screen for pathology of the bicipital tendon or rotator cuff injury.

**REFERRING VET**

Old Shore Animal  
Clinic

**INVOICE**

54210

**DATE**

9-21-22



**PATIENT**

Rocco Alagna

**SPECIES**

Canine

**BREED**

Bermese Mountain  
Dog

**SEX**

MN

**AGE**

8 Years

**INTERPRETED BY**

Sebastian Schaub, DVM  
Dr. med. vet. DipECVDI

**HOSPITAL NAME**

Animal Surgical  
Center

**REFERRING VET**

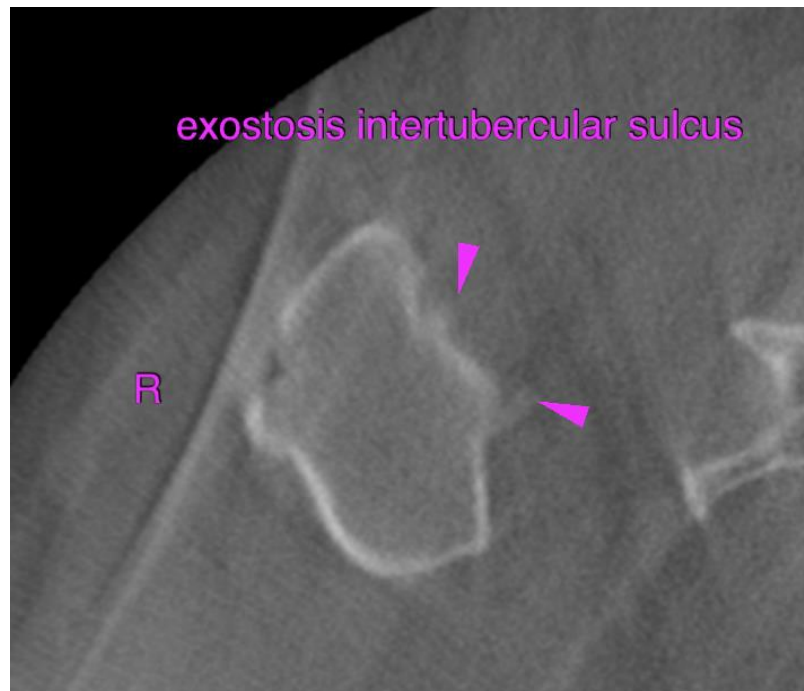
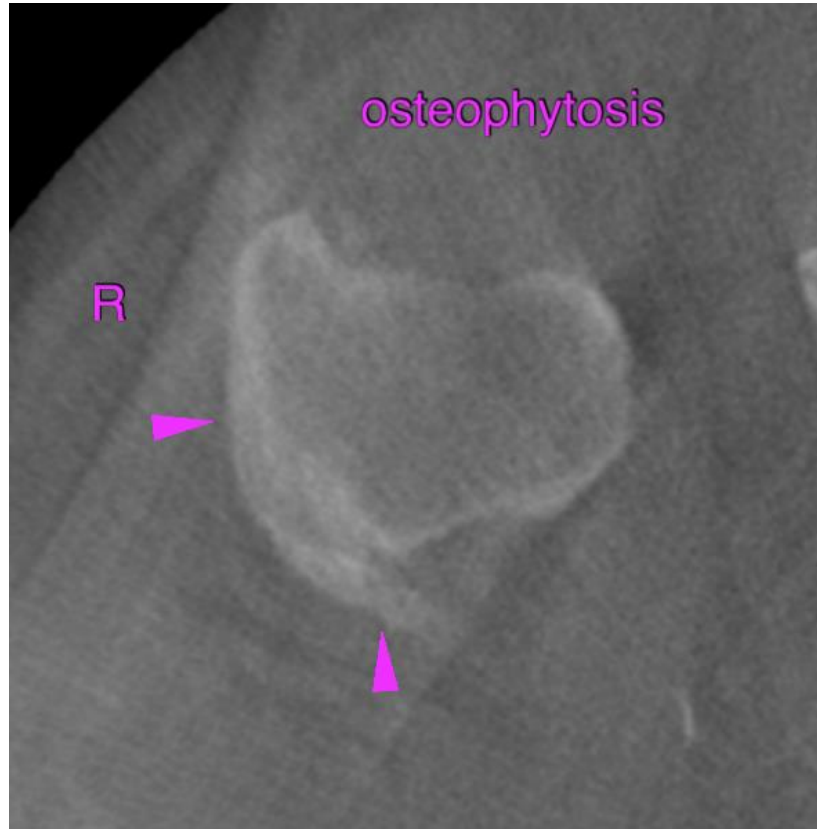
Old Shore Animal  
Clinic

**INVOICE**

54210

**DATE**

9-21-22





**PATIENT**

Rocco Alagna

**SPECIES**

Canine

**BREED**

Bermese Mountain  
Dog

**SEX**

MN

**AGE**

8 Years

**INTERPRETED BY**

Sebastian Schaub, DVM  
Dr. med. vet. DipECVDI

**HOSPITAL NAME**

Animal Surgical  
Center

**REFERRING VET**

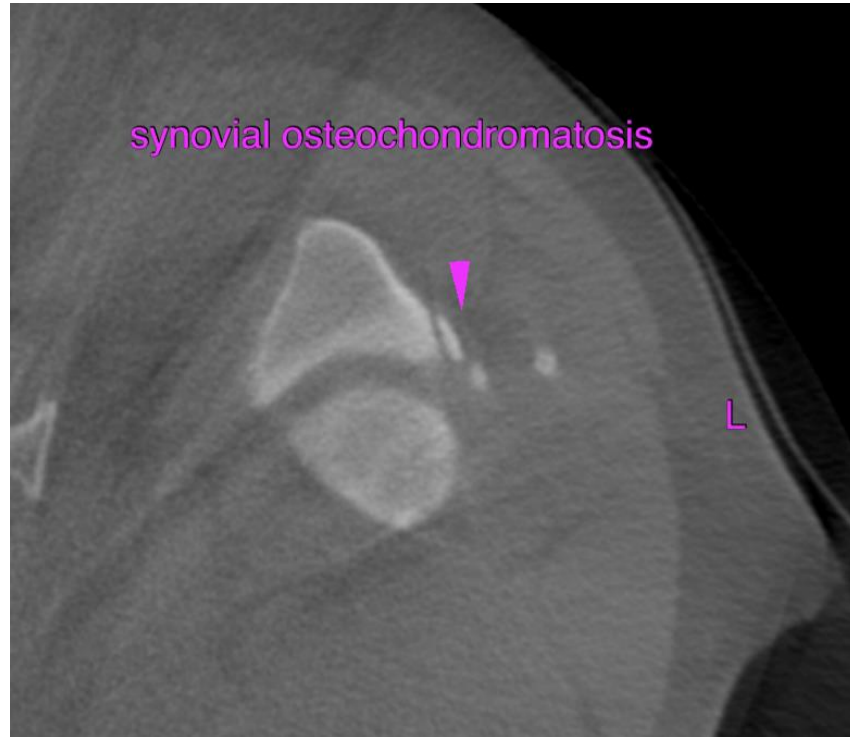
Old Shore Animal  
Clinic

**INVOICE**

54210

**DATE**

9-21-22



The information and recommendations provided are based on the images presented by the referring veterinarian/sonographer. No evaluation can be communicated regarding pathology that was not visible in the image/video clips provided.

Thank you for this referral. If the clinical or image interpretation does not parallel your findings or if I can be of any further assistance please contact me.

**Sebastian Schaub**, Sebastian Schaub, DVM, Dr. med. vet. DipECVDI  
sebast.schaub@gmail.com