



PATIENT PRESENTING CLINICAL SIGNS

Johnny Cuesta Sneezing, buphthalmos OD. Otitis

COMPUTED TOMOGRAPHY OF THE SKULL

SPECIES A high resolution pre- and post-contrast CT study of the skull is provided for review.

Canine **COMPUTED TOMOGRAPHIC FINDINGS**

The pictured parts of the dentition are complete and unremarkable in all jaw quadrants.

BREED In the caudal aspect of the right orbit, a soft tissue attenuating mass with mild amorphous mineralization is seen. The mass appears to be centered on the right perpendicular plate of the right palatine bone and is bulging into the nasal cavity, frontal sinuses. Destruction of the associated conchal structures is appreciated. The right ocular bulb is deviated ventrally and rostrally by the mass effect. The right frontal bone – in the region of the zygomatic process – presents permeative osteolytic lesions.

SEX Both temporomandibular joints present congruent joint spaces with even subchondral bone surfaces and are considered within normal limits.

Neutered Male

Both tympanic bullae are aerated, the mucosal lining is not seen, the bony wall is smooth and thin. The wall of the left external ear canals is prominent in comparison to the contralateral external ear canal.

AGE The brain presents no deviation from normal anatomy and symmetry. The brain parenchyma is homogeneous and within normal limits for attenuation and distribution of contrast enhancement. The ventricular system is non-dilated and symmetric.

10.8 Years

INTERPRETED BY The submandibular and medial retropharyngeal lymph nodes are small and elongated with a normal short-to-long-axis-ratio is < 0.5, the attenuation and contrast enhancement pattern is uniform.

Sebastian Schaub, DVM
Dr. med. vet. DipECVDI

Nodular enlargement of the right thyroid gland is noted, presenting a heterogeneous contrast enhancement pattern and measuring 2.0 x 1.8 x 2.7 cm in size.

HOSPITAL NAME COMPUTED TOMOGRAPHIC DIAGNOSIS

Mobile Pet Imaging

- Right retrobulbar & nasal mass with polyostotic aggressive osteolytic lesions of the right frontal bone and nasal bone
- Secondary right sided exophthalmos
- Nodular enlargement right thyroid gland
- Left sided otitis externa

REFERRING VET

Meaux

INTERPRETATION OF THE FINDINGS & FURTHER RECOMMENDATIONS

INVOICE The right sided retrobulbar & nasal mass is consistent with neoplasia and potentials include adenocarcinoma, osteosarcoma, squamous cell carcinoma, melanoma, fibrosarcoma, other. As the main component of the mass appears to be located in the right orbit, it might be primarily originate from the retrobulbar space with invasion of the nasal cavity. Recommend FNA sampling or biopsy of the mass for further workup. Based on the results of the advanced diagnostic tests, the chances of radiation therapy might be discussed with oncologist.

54203

DATE

9-21-22

The enlarged right thyroid gland can present a second entity and (non)functional thyroid carcinoma would be the top differential. Potentials include adenoma or nodular hyperplasia.



PATIENT

Johnny Cuesta

SPECIES

Canine

BREED

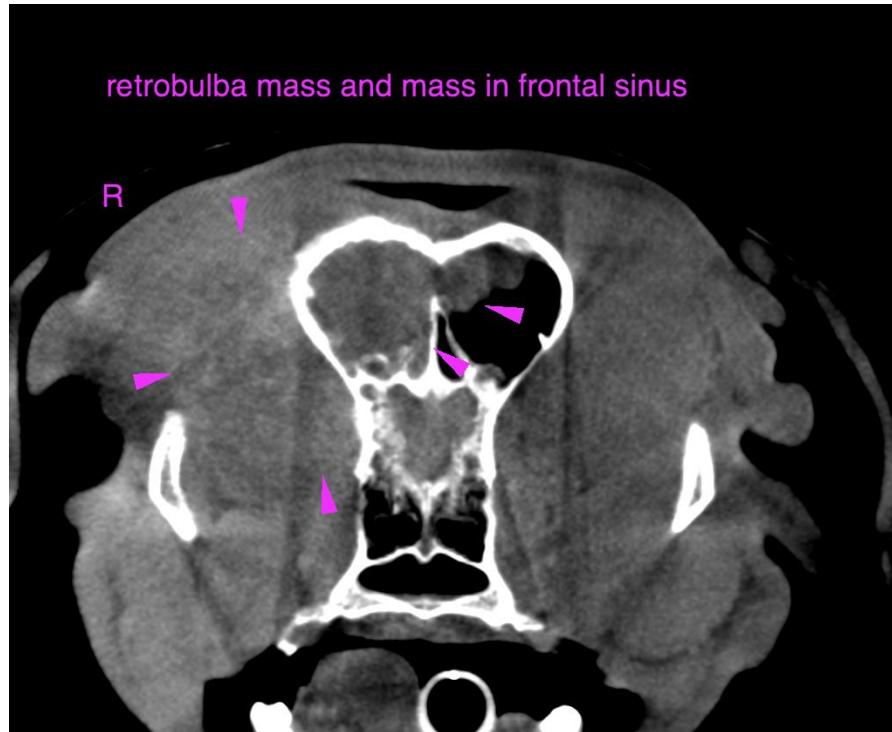
Mixed

SEX

Neutered Male

AGE

10.8 Years



retrobulba mass and mass in frontal sinus

INTERPRETED BY

Sebastian Schaub, DVM
Dr. med. vet. DipECVDI

HOSPITAL NAME

Mobile Pet Imaging

REFERRING VET

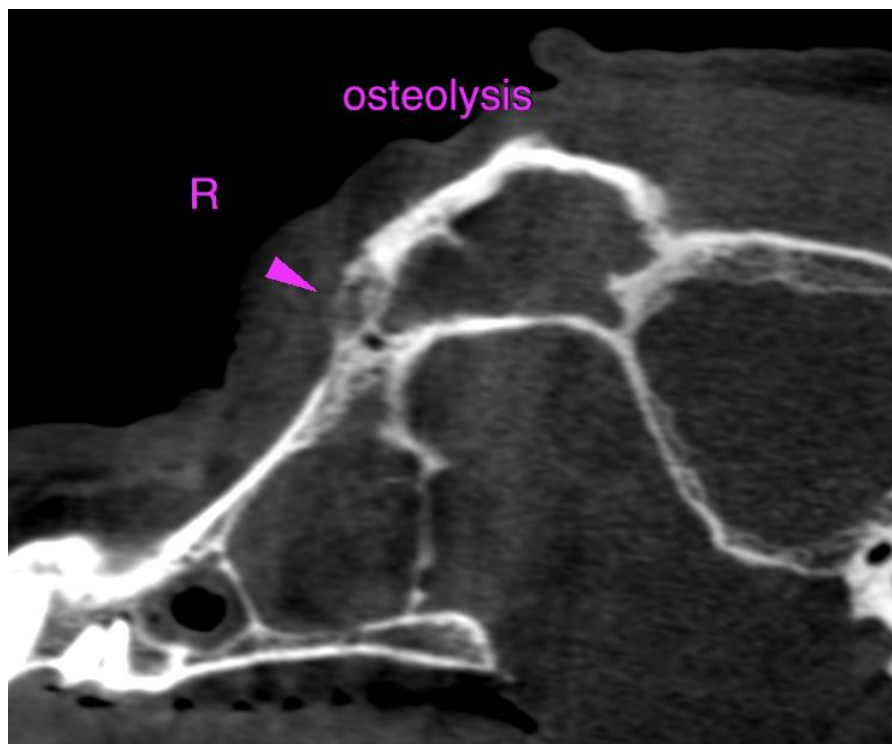
Meaux

INVOICE

54203

DATE

9-21-22



osteolysis



PATIENT

Johnny Cuesta

SPECIES

Canine

BREED

Mixed

SEX

Neutered Male

AGE

10.8 Years

INTERPRETED BY

Sebastian Schaub, DVM
Dr. med. vet. DipECVDI

HOSPITAL NAME

Mobile Pet Imaging

REFERRING VET

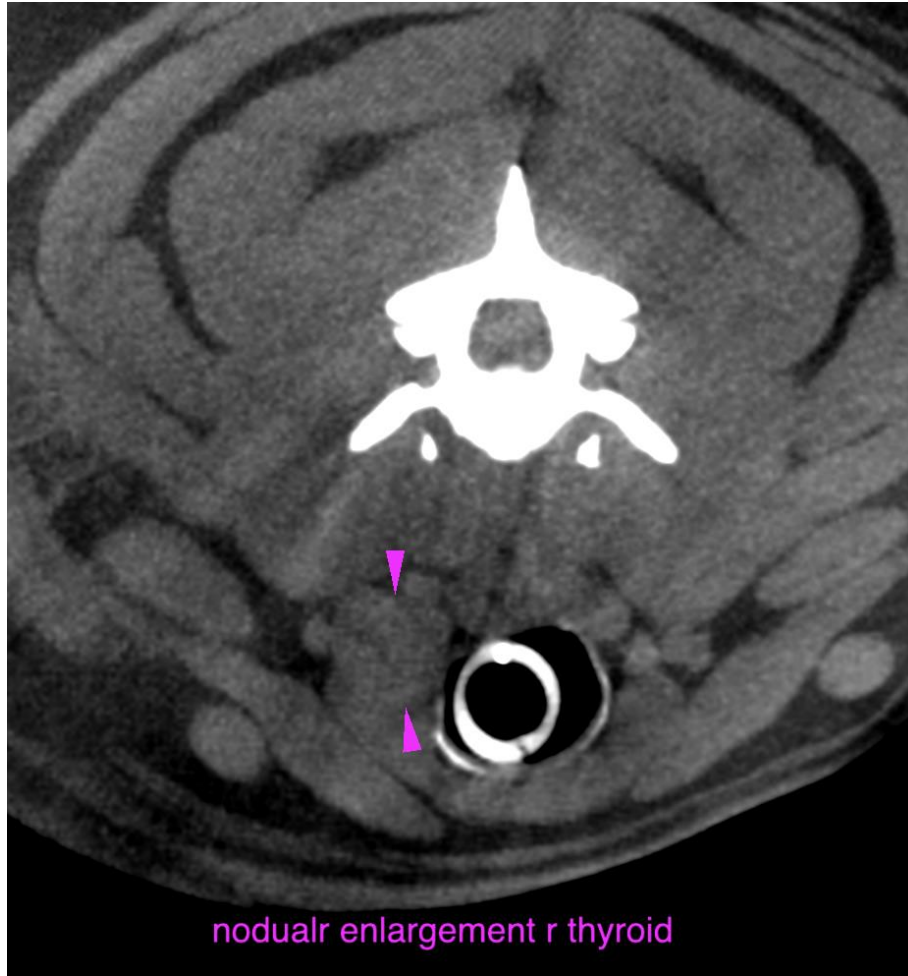
Meaux

INVOICE

54203

DATE

9-21-22



The information and recommendations provided are based on the images presented by the referring veterinarian/sonographer. No evaluation can be communicated regarding pathology that was not visible in the image/video clips provided.

Thank you for this referral. If the clinical or image interpretation does not parallel your findings or if I can be of any further assistance please contact me.

Sebastian Schaub, Sebastian Schaub, DVM, Dr. med. vet. DipECVDI
sebast.schaub@gmail.com