



**PATIENT**

Tenor Render

**PRESENTING CLINICAL SIGNS**

Two weeks ago noticed muscle wasting in hind end and skull. E/D normal. Dry hair coat. Occ pale mm, slight lethargy. Ultrasound shows possible intestinal neoplasia. Would like to know surgical options and if metastasized.

**SPECIES**

Canine

Abnormal PE/Chem/CBC/UA Results: Decreased RBC  $3 \times 10^{12}/L$ , HCT 19.3%, HGB 6.8 g/dL, ALB 21 g/L. Increased AMYL 2436 U/L

**BREED**

Bernese Mountain Dog

**COMPUTED TOMOGRAPHY OF THE ABDOMEN**

A high resolution pre- and post-contrast CT study of the abdomen is provided for review.

**COMPUTED TOMOGRAPHIC FINDINGS**

The serosal fat presents normal attenuation behavior. There is no evidence of peritoneal effusion or peritonitis.

**SEX**

MN

Both kidneys present within normal limits for size, shape and organ architecture. After contrast administration a bilaterally symmetric and uniform nephro- and pyelogram is noted.

The adrenal glands are within normal limits for size, shape and organ architecture.

**AGE**

9 Years

Both liver and spleen present with normal shape, even surface, uniformly attenuating parenchyma and homogeneous contrast enhancement, unremarkable.

**INTERPRETED BY**

Sebastian Schaub, DVM  
Dr. med. vet. DipECVDI

The gallbladder is moderately distended and contains a moderate amount of mineralizing gallbladder sludge.

The pancreas is evenly contoured, the pancreatic parenchyma is homogeneous and presents uniform contrast enhancement.

**HOSPITAL NAME**

Bridgewater Veterinary Hospital and Wellness Centre

The descending duodenum up to the caudal duodenal flexure presents a segmental circumferential moderate to marked eccentric irregular mural thickening of the wall measuring up to 2.5 cm in width. The duodenal segment is measuring approximately 10 cm in length. Post contrast administration the wall-layering is lost.

The jejunal lymph node is moderately enlarged, rounded, uniform soft tissue attenuating with a heterogeneous contrast enhancement patten.

**REFERRING VET**

Dr. M. Sra

Multifocal spondylosis formation is seen along the lumbar spine. Multiple intervertebral discs of the lumbar spine are mild to moderately protruding into the vertebral canal. Both coxofemoral joints present mild osteophyte new bone formation.

**INVOICE**

47484

**COMPUTED TOMOGRAPHIC DIAGNOSIS**

- Segmental mural mass descending duodenum
- Lymphadenopathy jejunal lymph node
- Moderate biliary sludge
- Multifocal intervertebral disc protrusion along the lumbar spine with potential spinal cord compression

**DATE**

9-21-21



**PATIENT**

Tenor Render

- Spondylosis deformans
- Degenerative osteoarthritis coxofemoral joints bilaterally

**SPECIES**

Canine

**BREED**

Bernese Mountain  
Dog

**SEX**

MN

**AGE**

9 Years

**INTERPRETED BY**

Sebastian Schaub, DVM  
Dr. med. vet. DipECVDI

**HOSPITAL NAME**

Bridgwater  
Veterinary Hospital  
and Wellness Centre

**REFERRING VET**

Dr. M. Sra

**INVOICE**

47484

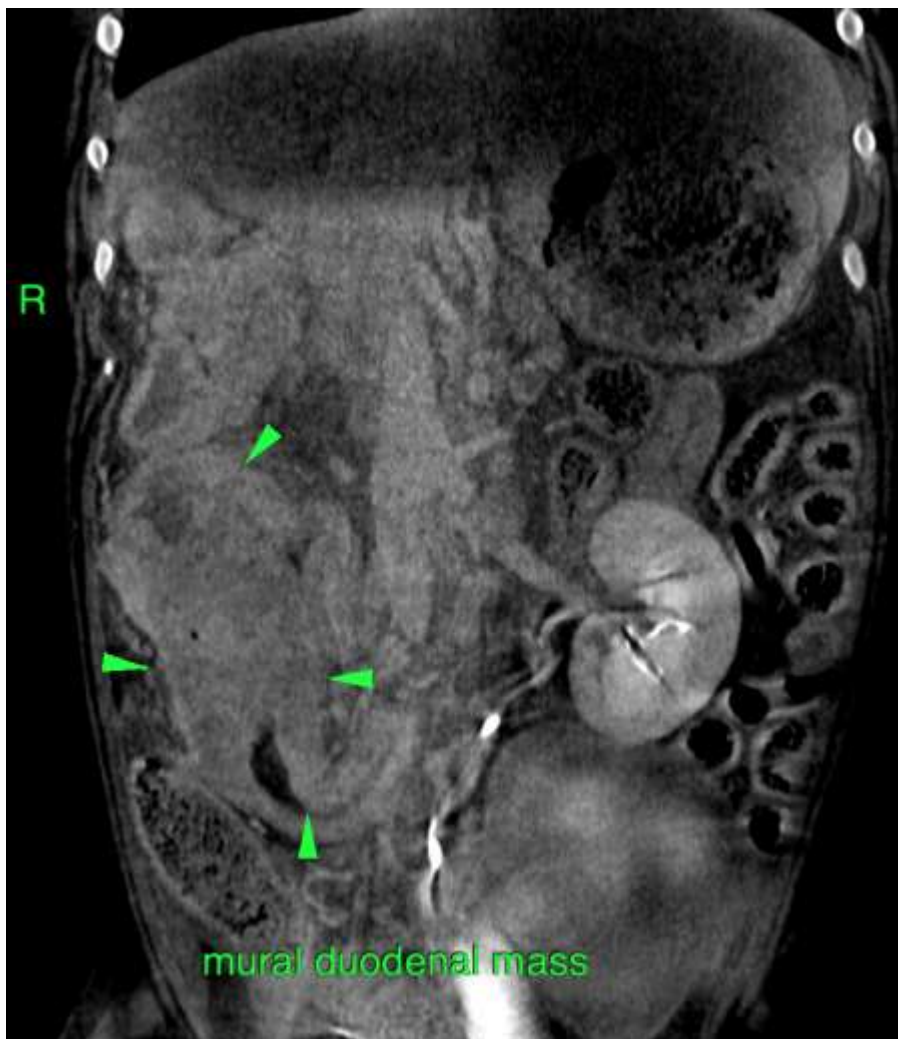**DATE**

9-21-21

**INTERPRETATION OF THE FINDINGS & FURTHER RECOMMENDATIONS**

The findings are consistent with neoplastic transformation of a duodenal segment and metastatic spread to the regional lymph nodes. Although surgical excision of the intestinal mass by enterectomy is feasible, surgical excision of the lymph node metastasis is not possible. Consider FNA sampling of the mass for definition of the tumor type and decision making if surgery in combination with adjuvant chemotherapy would be an option.

Recommend full tumor staging.





**PATIENT**

Tenor Render

**SPECIES**

Canine

**BREED**

Bernese Mountain  
Dog

**SEX**

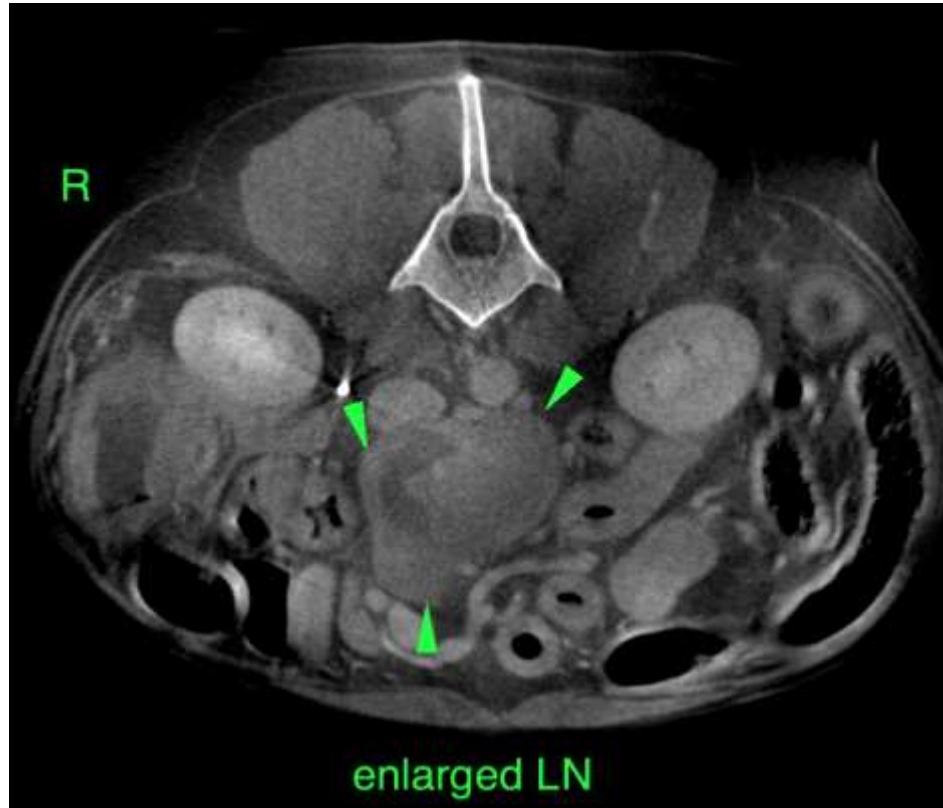
MN

**AGE**

9 Years

**INTERPRETED BY**

Sebastian Schaub, DVM  
Dr. med. vet. DipECVDI



**HOSPITAL NAME**

Bridgwater  
Veterinary Hospital  
and Wellness Centre

**REFERRING VET**

Dr. M. Sra

**INVOICE**

47484

**DATE**

9-21-21

The information and recommendations provided are based on the images presented by the referring veterinarian. No evaluation can be communicated regarding pathology that was not visible in the image/video clips provided.

Thank you for this referral. If the clinical or image interpretation does not parallel your findings or if I can be of any further assistance please contact me.

**Sebastian Schaub**, Sebastian Schaub, DVM, Dr. med. vet. DipECVDI  
sebast.schaub@gmail.com