



PATIENT PRESENTING CLINICAL SIGNS

PATIENT Raider Garcia
HISTORY: Pt presented for sneezing episodes and nasal discharge fro over a year. RDVM attempted to treat with multiple courses of medications including Clavamox, Clindamicin, Revolution and a cytopoint injection. This brought no improvement. DVM referred to MWVS for CT and rhinoscopy.
Abnormal PE/Chem/CBC/UA Results:

SPECIES

Canine

COMPUTED TOMOGRAPHIC STUDY OF THE SKULL

A high resolution pre- and post-contrast CT study of the skull is provided for review.

BREED

American
Staffordshire Terrier
Mix

COMPUTED TOMOGRAPHIC FINDINGS

The tooth elements 208 and 306 are absent.

In both nasal cavities a moderate to marked amount of non-contrast enhancing soft tissue attenuating material is attached to the nasal mucosal lining. The left frontal sinus contains a moderate amount of gravity dependent soft tissue material, forming a horizontal gas-fluid interface. Mild atrophy of the nasal conchal structures is present.

SEX

Neutered Male

Both temporomandibular joints present congruent joint spaces with even subchondral bone surfaces and are considered within normal limits.

AGE

7 Years

Both tympanic bullae are aerated, the mucosal lining is not seen, the bony wall is smooth and thin. The external ear canals are within normal limits.

The brain presents no deviation from normal anatomy and symmetry. The brain parenchyma is homogeneous and within normal limits for attenuation and distribution of contrast enhancement. The ventricular system is non-dilated and symmetric.

INTERPRETED BY

Sebastian Schaub,
DVM Dr. med. vet.
DipECVDI

The mandibular lymph nodes are mildly prominent; the short-to-long-axis ratio is maintained normal <0.5.

COMPUTED TOMOGRAPHIC DIAGNOSIS

HOSPITAL NAME

Mountain West VH

- Mild destructive rhinitis and sinusitis
- Mild lymphadenopathy mandibular lymph nodes
- Absent triadan 208 and 306

REFERRING VET

Melanie Thompson

INTERPRETATION OF THE FINDINGS & FURTHER RECOMMENDATIONS

The computed tomographic findings are compatible with chronic non-specific rhinitis.

INVOICE

13221

Possible causes of the rhinitis/sinusitis can be either viral or immune-mediated (most common form would be lymphocytic-plasmacytic) rhinitis with bacterial superinfection. The changes noted are not typical of fungal rhinitis or a foreign body related rhinitis. There is no evidence of neoplastic disease. Suspect secondary reactive hyperplasia of the regional lymph nodes.

DATE

9/21/21



PATIENT

Raider Garcia

SPECIES

Canine

BREED

American
Staffordshire Terrier
Mix

SEX

Neutered Male

AGE

7 Years

INTERPRETED BY

Sebastian Schaub,
DVM Dr. med. vet.
DipECVDI

HOSPITAL NAME

Mountain West VH

REFERRING VET

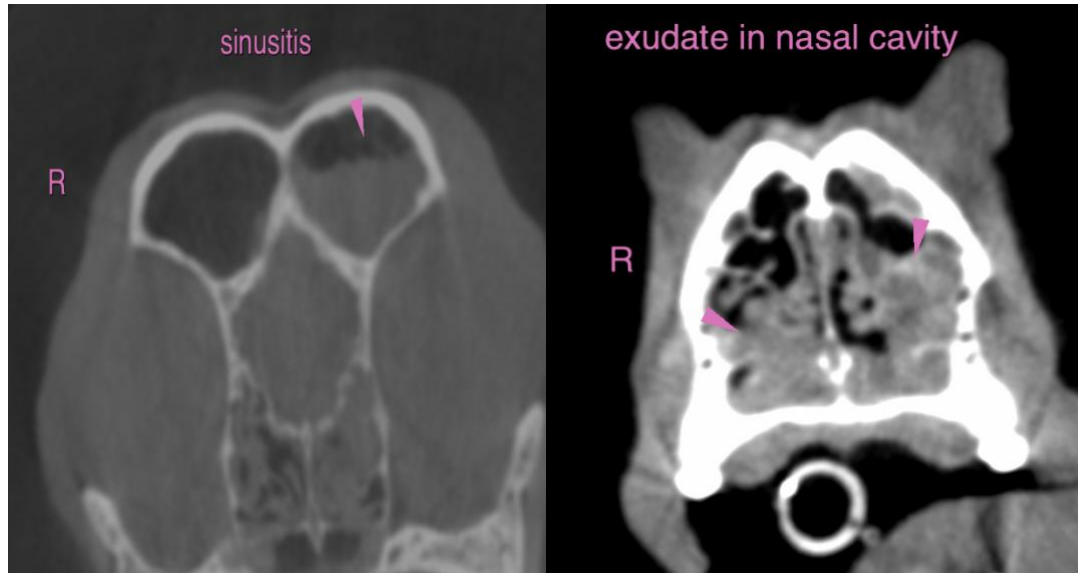
Melanie Thompson

INVOICE

13221

DATE

9/21/21



The information and recommendations provided are based on the images presented by the referring veterinarian. No evaluation can be communicated regarding pathology that was not visible in the image/video clips provided.

Thank you for this referral. If the clinical or image interpretation does not parallel your findings or if I can be of any further assistance please contact me.

Sebastian Schaub, Sebastian Schaub, DVM, Dr. med. vet. DipECVDI
sebast.schaub@gmail.com