



**PATIENT PRESENTING CLINICAL SIGNS**

Midnight Worley History: Sick Sneezes and boogers come out Eating ok Not drinking a lot of water Pet gagged twice but no vomiting O has pretty kitty litter and when P urinates the litter is turning blue Had diarrhea twice - better now - O brought in a stool sample Hacking No vomiting

**SPECIES**

Feline

Abnormal PE/Chem/CBC/UA Results: Radiographs- send for review UA to lab via cysto- pending Cerenia 0.2ml SQ disp Clavamox 62.5mg/ml 0.5ml BID for 10 days recommended recheck if not better in 3-5 days, or sooner if develops vomiting or coughing or any other abnormality

**BREED**

DSH

**RADIOGRAPHIC STUDY OF THE THORAX AND ABDOMEN**

A complete set of radiographs of the thorax and abdomen is provided for review.

**RADIOGRAPHIC FINDINGS**

**SEX**

Thorax

Male

The surrounding bony structures are within normal limits.

**AGE**

5 Months

The extrathoracic soft tissues present homogeneous without abnormalities.

The heart is of normal size and shape, there is no evidence of cardiac chamber or vascular enlargement. The pulmonary vasculature is within normal limits.

**INTERPRETED BY**

Sebastian Schaub,  
DVM Dr. med. vet.  
DipECVDI

The cranial mediastinum presents the expected soft tissue opacity. The mediastinal width is less than twice the width of the vertebral column at the same level.

The trachea is normal in diameter and presents the anticipated course. The luminal outline of the trachea is smooth.

Moderta thickening of the bronchial walls is seen.

**HOSPITAL NAME**

Animal Paradise H

The lung parenchyma presents the expected architecture and opacity; the intrapulmonary vascular branching is seen up to the third order lung vessels.

**REFERRING VET**

Dr. Kristin Hellwarth

The diaphragm is well delineated with even surface and the expected mild cranial bulging of the diaphragmatic cupola.

**Abdomen**

**INVOICE**

13227

The surrounding bony structures are within normal limits.

No abnormalities of the extraabdominal soft tissues are noted. The abdominal wall is smooth and thin. The serosal detail is decreased, due to lack of peritoneal fat.

**DATE**

9/21/21

The liver is appropriate in position, size and presents uniform opacity.

The splenic head is in the anticipated position and within normal limits for size and opacity.



**PATIENT**

Midnight Worley Both kidneys are seen and present with normal size, shape, delineation and opacity. The urinary bladder is in its anticipated position. No radiopaque calculi are noted throughout the upper and lower urinary tract.

**SPECIES**

Feline The stomach is in its anticipated position and presents normal content. The small intestinal loops are of even diameter and non-dilated, a small amount of gas and ingesta is seen within the small intestinal loops.

**BREED**

DSH The colon is seen in the expected position and presents with appropriate content.

**RADIOGRAPHIC DIAGNOSIS**

- Bronchial lung pattern
- Normal abdomen with mild gas and ingesta pattern of the intestinal tract

**SEX**

Male

**INTERPRETATION OF THE FINDINGS & FURTHER RECOMMENDATIONS**

**AGE**

5 Months

There is a mild bronchial lung pattern, indicating inflammatory lower airway disease possible secondary to the clinically described upper respiratory tract infection. Empirical treatment has already been started.

The abdomen presents without pathological findings.

**INTERPRETED BY**

Sebastian Schaub,  
DVM Dr. med. vet.  
DipECVDI

**HOSPITAL NAME**

Animal Paradise H

**REFERRING VET**

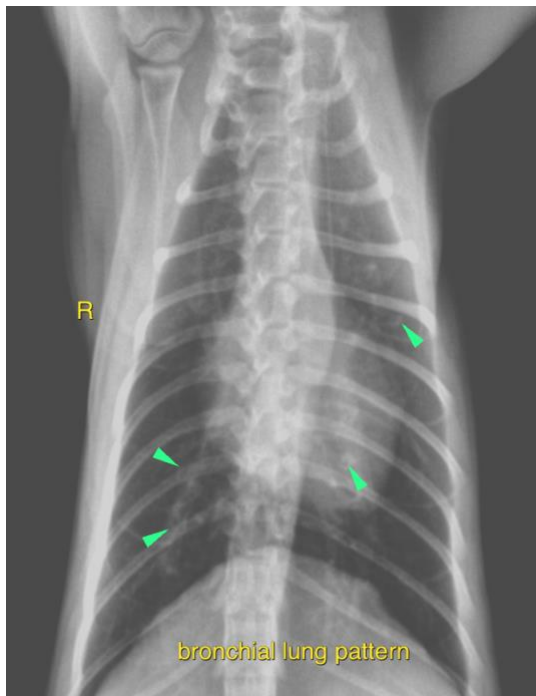
Dr. Kristin Hellwarth

**INVOICE**

13227

**DATE**

9/21/21





**PATIENT**

Midnight Worley

The information and recommendations provided are based on the images presented by the referring veterinarian. No evaluation can be communicated regarding pathology that was not visible in the image/video clips provided.

**SPECIES**

Feline

Thank you for this referral. If the clinical or image interpretation does not parallel your findings or if I can be of any further assistance please contact me.

**Sebastian Schaub**, Sebastian Schaub, DVM, Dr. med. vet. DipECVDI  
sebast.schaub@gmail.com

**BREED**

DSH

**SEX**

Male

**AGE**

5 Months

**INTERPRETED BY**

Sebastian Schaub,  
DVM Dr. med. vet.  
DipECVDI

**HOSPITAL NAME**

Animal Paradise H

**REFERRING VET**

Dr. Kristin Hellwarth

**INVOICE**

13227

**DATE**

9/21/21