



PATIENT PRESENTING CLINICAL SIGNS

PATIENT Marshmallow
CAMERAS Cameros
HISTORY: Marshmallow presented to us today with a seizure like episode Owner is not sure if it is a seizure or syncope. On physical exam Marshmallow has grade 3 heart murmur more prominent on the left side. Needs second opinion on chest and heart

SPECIES Abnormal PE/Chem/CBC/UA Results:

CANINE **RADIOGRAPHIC STUDY OF THE THORAX**

Radiographs of the thorax in three imaging planes are provided for review.

BREED RADIOGRAPHIC FINDINGS

Cockapoo The surrounding bony structures are within normal limits.

SEX The extrathoracic soft tissues present homogeneous without abnormalities.

Male The caudal contour of the cardiac silhouette is steep and the caudal cardiac waist is lost. A wedge shaped soft tissue opacity is visible level with the left atrium. The left principal bronchus is mildly elevated. The pulmonary vasculature is within normal limits.

AGE The cranial mediastinum presents the expected soft tissue opacity. The mediastinal width is less than twice the width of the vertebral column at the same level.

11 Years The trachea is normal in diameter and presents the anticipated course. The luminal outline of the trachea is smooth.

INTERPRETED BY The bronchial tree presents with thin walls and tapers uniformly towards the periphery as expected. The lung parenchyma presents the expected architecture and opacity; the intrapulmonary vascular branching is seen up to the third order lung vessels.

Sebastian Schaub,
 DVM Dr. med. vet.
 DipECVDI

HOSPITAL NAME The diaphragm is well delineated with even surface and the expected mild cranial bulging of the diaphragmatic cupola.

Truscott AH **RADIOGRAPHIC DIAGNOSIS**

- Left atrial enlargement without evidence of decompensation

REFERRING VET INTERPRETATION OF THE FINDINGS & FURTHER RECOMMENDATIONS

Dr. Medhat Meawad There is mild to moderate enlargement of the left atrium visible, in combination with the cardiac murmur insufficiency of the mitral valve due to myxomatous mitral valve degeneration is the top differential. A cardiac echo can be used for further evaluation of cardiac chamber size and function.

INVOICE

13230

DATE

9/21/21



PATIENT

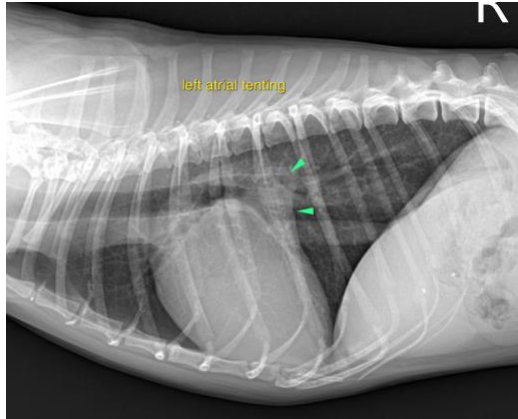
Marshmallow
Cameros

SPECIES

Canine

BREED

Cockapoo



SEX

Male

AGE

11 Years

The information and recommendations provided are based on the images presented by the referring veterinarian. No evaluation can be communicated regarding pathology that was not visible in the image/video clips provided.

Thank you for this referral. If the clinical or image interpretation does not parallel your findings or if I can be of any further assistance please contact me.

Sebastian Schaub, Sebastian Schaub, DVM, Dr. med. vet. DipECVDI
sebast.schaub@gmail.com

INTERPRETED BY

Sebastian Schaub,
DVM Dr. med. vet.
DipECVDI

HOSPITAL NAME

Truscott AH

REFERRING VET

Dr. Medhat Meawad

INVOICE

13230

DATE

9/21/21