



PATIENT

Roxy Anderson

PRESENTING CLINICAL SIGNS

Right pelvic limb lameness for 6 months.

SPECIES

Feline

COMPUTED TOMOGRAPHY OF THE HIND LIMB

A high resolution plain CT study of the right hind limb is provided for review.

BREED

Domestic Medium
Hair

COMPUTED TOMOGRAPHIC FINDINGS

The epiphysis of the right femoral head is separated from the neck and the femoral epiphysis, and the neck present generalized moderate sclerosis with mild new bone formation.

The right stifle joint presents smooth osseous margins and without signs of intracapsular swelling.

There is moderate overexposure, and the soft tissues of the tarsal joint are partially burned out.

SEX

MN

The right talocrural joint presents smooth osseous margins and the joint space is congruent, unremarkable. The remainder of the osseous structures of the right tarsal joint present without abnormalities.

The included part of the metacarpal region are within normal limits.

AGE

2 Years

COMPUTED TOMOGRAPHIC DIAGNOSIS

- Chronic right sided epiphysiolysis of the femoral head
- Normal right stifle joint
- Normal right tarsal joint

INTERPRETED BY

Sebastian Schaub, DVM
Dr. med. vet. DipECVDI

INTERPRETATION OF THE FINDINGS & FURTHER RECOMMENDATIONS

The chronic epiphysiolysis of the right femoral head is a plausible explanation for the presenting clinical signs. The therapy of choice is femoral head ostectomy. This condition can be the results of trauma or present an ossification disorder due to slipped capital femoral epiphysis. The latter can occur bilaterally – in the current CT study the left femoral head appears unremarkable.

HOSPITAL NAME

Paws and Claws
Urgent Care

REFERRING VET

Shakira Jameson

INVOICE

54174

DATE

9-20-22



PATIENT

Roxy Anderson

SPECIES

Feline

BREED

Domestic Medium
Hair

SEX

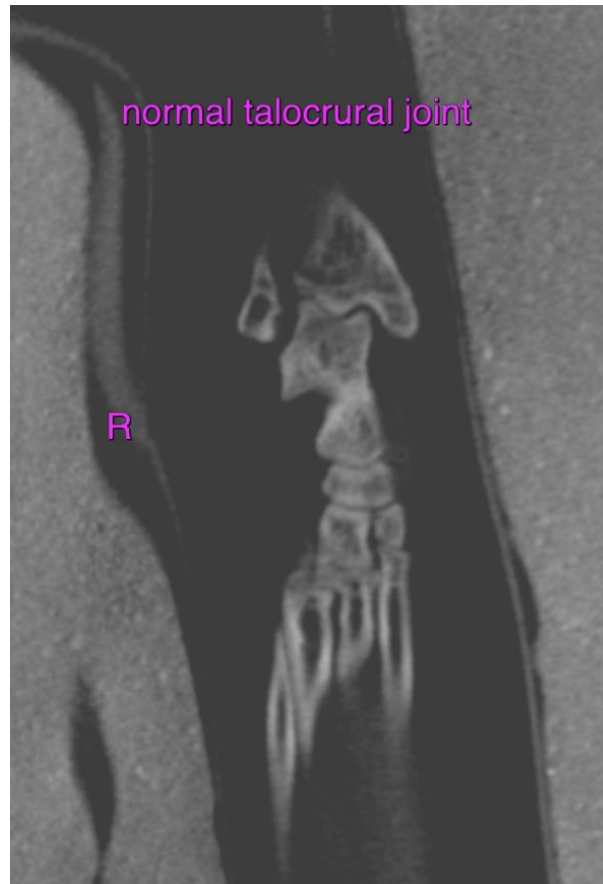MN

AGE

2 Years

INTERPRETED BY

Sebastian Schaub, DVM
Dr. med. vet. DipECVDI



HOSPITAL NAME

Paws and Claws
Urgent Care

REFERRING VET

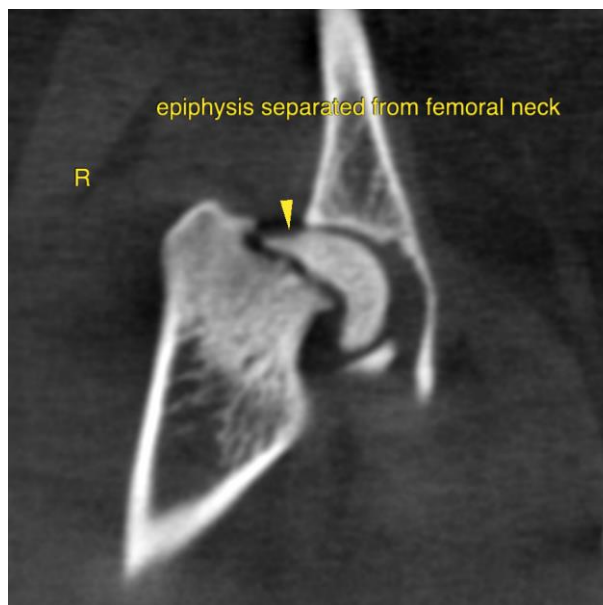
Shakira Jameson

INVOICE

54174

DATE

9-20-22





PATIENT

Roxy Anderson

SPECIES

Feline

BREED

Domestic Medium
Hair

SEX

MN

AGE

2 Years

INTERPRETED BY

Sebastian Schaub, DVM
Dr. med. vet. DipECVDI

HOSPITAL NAME

Paws and Claws
Urgent Care

REFERRING VET

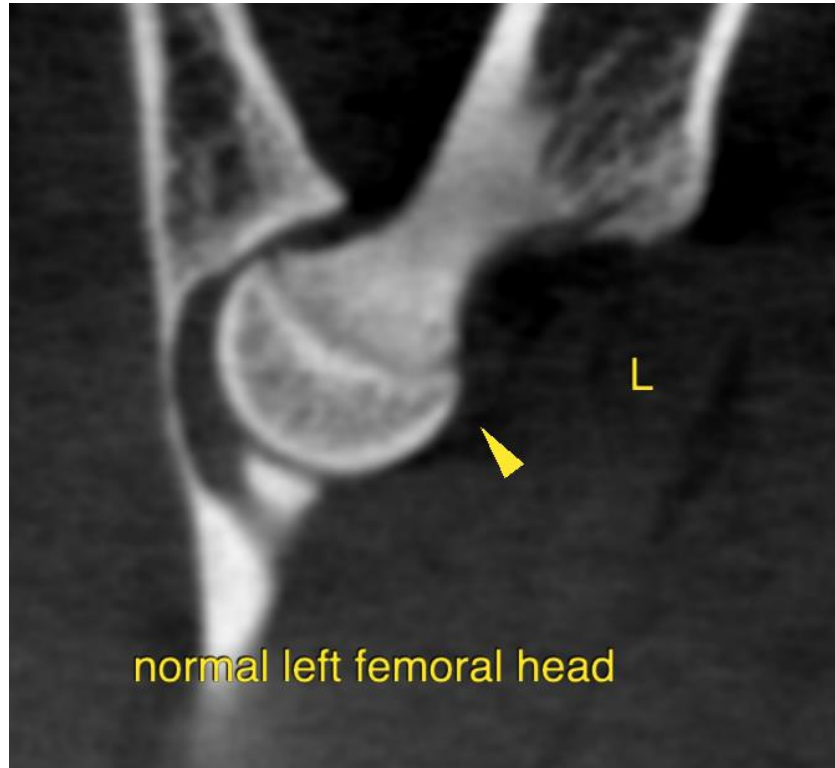
Shakira Jameson

INVOICE

54174

DATE

9-20-22



The information and recommendations provided are based on the images presented by the referring veterinarian/sonographer. No evaluation can be communicated regarding pathology that was not visible in the image/video clips provided.

Thank you for this referral. If the clinical or image interpretation does not parallel your findings or if I can be of any further assistance please contact me.

Sebastian Schaub, Sebastian Schaub, DVM, Dr. med. vet. DipECVDI
sebast.schaub@gmail.com