



PATIENT PRESENTING CLINICAL SIGNS

Cosimo Wilson Hx chronic rhinitis with bilateral mucopurulent discharge from nostrils, mass on LF paw pad
Abnormal PE/Chem/CBC/UA Results:

SPECIES COMPUTED TOMOGRAPHY OF THE SKULL, THORAX AND ABDOMEN

Feline A pre- and post-contrast CT study of the skull, thorax and abdomen in a soft tissue reconstruction is provided for review.

COMPUTED TOMOGRAPHIC FINDINGS

BREED

Skull

DSH

All teeth but the maxillary and mandibular incisor teeth and the mandibular canine teeth are absent. Moderate atrophy of the alveolar bone in all jaw quadrants is appreciated.

SEX

In both nasal cavities, advanced destruction of the nasal conchal & turbinate structures is appreciated and a mild amount of non-contrast enhancing material is attached to a thickened nasal mucosal lining.

MN

AGE

Both temporomandibular joints present congruent joint spaces with even subchondral bone surfaces and are considered within normal limits.

17 Years

The left tympanic bulla is moderately filled with gravity dependent, soft tissue attenuating material, the wall is mildly thickened and smooth.. The external ear canals are within normal limits.

INTERPRETED BY

Sebastian Schaub, DVM
Dr. med. vet. DipECVDI

The brain presents no deviation from normal anatomy and symmetry. The brain parenchyma is homogeneous and within normal limits for attenuation and distribution of contrast enhancement. The ventricular system is non-dilated and symmetric.

HOSPITAL NAME

Animal Health
Partners

The submandibular and medial retropharyngeal lymph nodes are small and elongated with a normal short-to-long-axis-ratio is < 0.5, the attenuation and contrast enhancement pattern is uniform.

Nodular enlargement of the right thyroid gland is seen, presenting a mild heterogeneous contrast enhancement pattern and measuring 7.0 mm in diameter.

REFERRING VET

Westgarth

Thorax

Level with the cranial thoracic aperture, ventral to the trachea, two uniform soft tissue attenuating nodular lesions are appreciated, measuring up to 15 x 20 x 15 mm in size; post contrast administration the nodular lesions present with a contrast enhancing wall with contrast enhancing material bulging into a fluid attenuating center.

INVOICE

54184

The left superficial cervical lymph node is prominent and presents with ha heterogeneous contrast enhancement pattern.

DATE

9-20-22

The sternal, cranial mediastinal and tracheobronchial lymph nodes are small elongated with a normal short-to-long-axis-ratio is < 0.5, the attenuation and contrast enhancement pattern is uniform and considered within normal limits.

The cardiovascular structures including the pulmonary vasculature are within normal limits.

Generalized mild to moderate smooth thickening of the bronchial walls is appreciated.



PATIENT

The lung parenchyma presents the expected architecture and attenuation behavior.

Cosimo Wilson

Small incidental gas pockets are seen within the esophageal lumen, there is no evidence of abnormal dilation.

SPECIES

Abdomen

Feline

The serosal fat presents normal attenuation behavior. There is no evidence of peritoneal effusion or peritonitis.

BREED

DSH

Both kidneys present within normal limits for size, shape and organ architecture. After contrast administration a bilaterally symmetric and uniform nephro- and pyelogram is noted.

The adrenal glands are within normal limits for size, shape and organ architecture.

SEX

MN

Both liver and spleen present with normal shape, even surface, uniformly attenuating parenchyma and homogeneous contrast enhancement, unremarkable.

The pancreas is evenly contoured, the pancreatic parenchyma is homogeneous and presents uniform contrast enhancement.

AGE

17 Years

The position, delineation, wall and content of the gastrointestinal tract are considered within normal limits throughout.

The bony and surrounding soft tissue structures reveal no abnormalities.

COMPUTED TOMOGRAPHIC DIAGNOSIS

INTERPRETED BY

Sebastian Schaub, DVM
Dr. med. vet. DipECVDI

- Destructive rhinitis
- Lymphadenopathy right superficial cervical lymph node
- Cavitory soft tissue nodules ventral to trachea level with thoracic inlet
- Nodular enlargement right thyroid gland
- Left sided otitis media
- History of full mouth extraction with few remaining teeth
- No evidence of pulmonary metastatic disease

HOSPITAL NAME

Animal Health
Partners

INTERPRETATION OF THE FINDINGS & FURTHER RECOMMENDATIONS

REFERRING VET

Westgarth

The findings are consistent with chronic destructive rhinitis. The causative agent is most likely primary viral ± bacterial superinfection. Even though unlikely there is a small chance of emerging fungal (cryptococcal) superinfection.

Rhinoscopy with biopsy and samples for microbial cultures can be used for further evaluation. Clinical signs are likely to reoccur in cases of chronic rhinosinusitis.

INVOICE

54184

The nodular lesions level with the thoracic inlet are most suggestive for cystic enlargement of ectopic thyroid tissue and in combination with the nodular enlargement of the right thyroid gland (non)functional thyroid adenoma is the top differential.

DATE

9-20-22

In combination with the mass at the left front paw, the enlarged left superficial cervical lymph node is concerning for metastatic disease, recommend FNA sampling to confirm the diagnosis.



PATIENT

Cosimo Wilson

SPECIES

Feline

BREED

DSH

SEX

MN

AGE

17 Years

INTERPRETED BY

Sebastian Schaub, DVM
Dr. med. vet. DipECVDI

HOSPITAL NAME

Animal Health
Partners

REFERRING VET

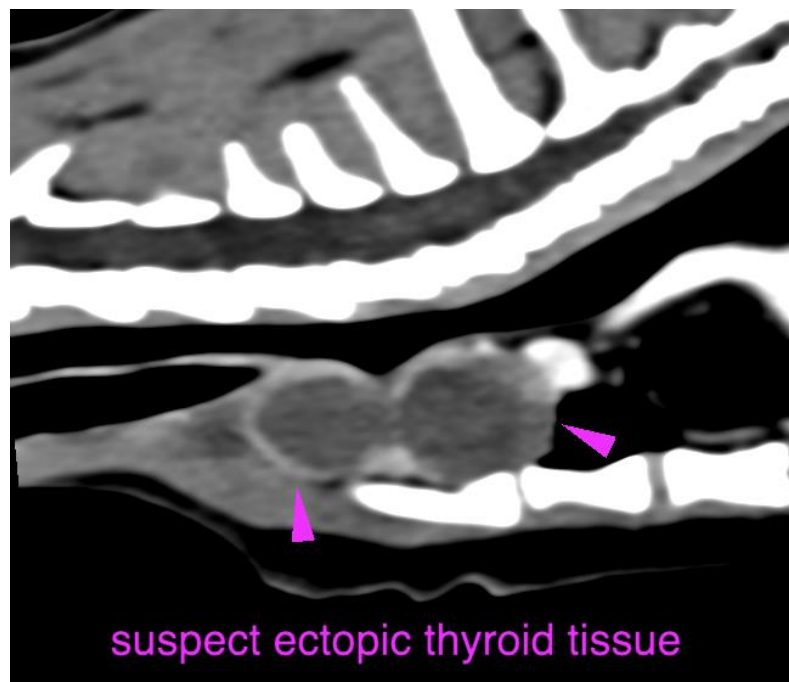
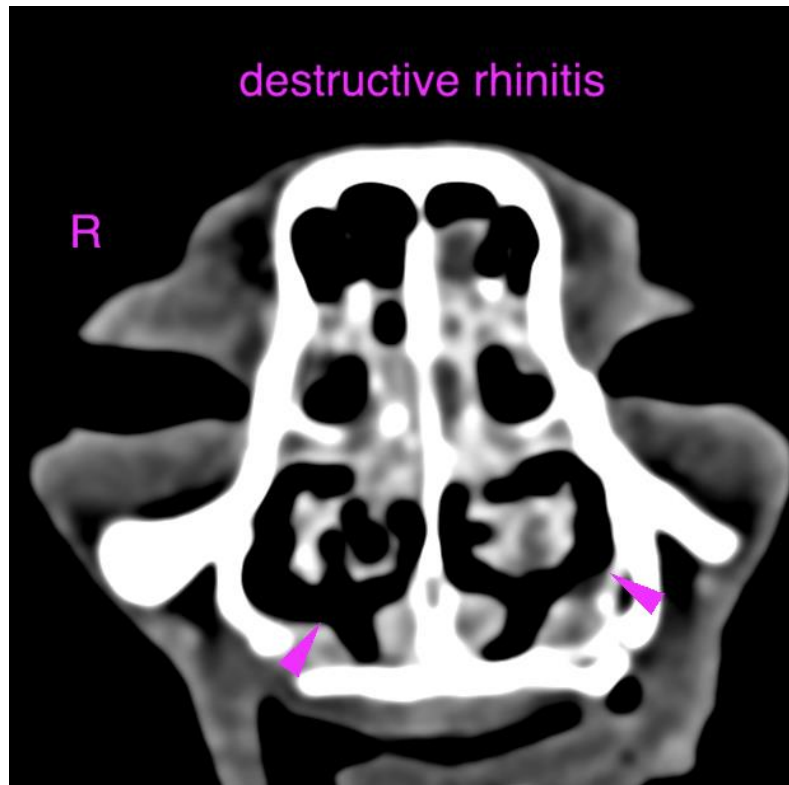
Westgarth

INVOICE

54184

DATE

9-20-22





PATIENT

Cosimo Wilson

SPECIES

Feline

BREED

DSH

SEX

MN

AGE

17 Years

INTERPRETED BY

Sebastian Schaub, DVM
Dr. med. vet. DipECVDI

HOSPITAL NAME

Animal Health
Partners

REFERRING VET

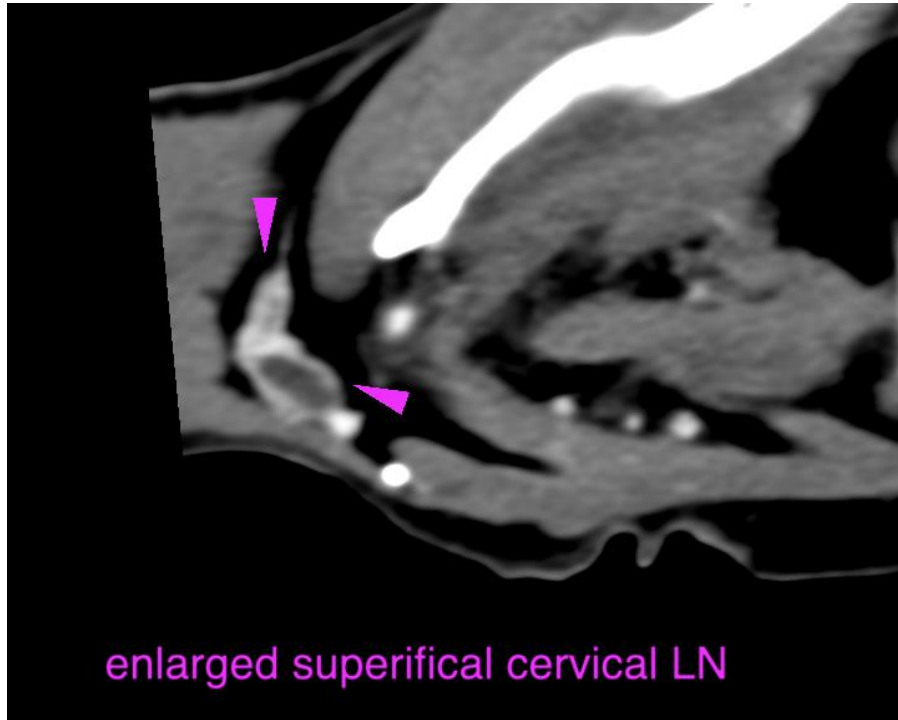
Westgarth

INVOICE

54184

DATE

9-20-22



The information and recommendations provided are based on the images presented by the referring veterinarian/sonographer. No evaluation can be communicated regarding pathology that was not visible in the image/video clips provided.

Thank you for this referral. If the clinical or image interpretation does not parallel your findings or if I can be of any further assistance please contact me.

Sebastian Schaub, Sebastian Schaub, DVM, Dr. med. vet. DipECVDI
sebast.schaub@gmail.com