



PATIENT PRESENTING CLINICAL SIGNS

PATIENT
Chewy Duenas

SPECIES
Feline

BREED
Domestic Short Hair

SEX
M

AGE
12

INTERPRETED BY
Sebastian Schaub, DVM
Dr. med. vet. DipECVDI

P is a 12 year old Male Neutered DSH who presented 1 month ago with a right sided facial swelling, nasal discharge (mucoïd), and blepharospasm. P was started on antibiotics (amoxicillin/clav acid) along with NSAIDs. A dentistry procedure was performed with many extractions from the upper right quadrant (100's). Antibiotics and NSAIDs continued for one week past procedure. At recheck examination, much improvement noted; however, right sinus region still appeared swollen. O had to leave town, so we elected to treat with more broad spectrum antibiotics and NSAIDs until she returned. Recheck on 9/14 revealed no further improvement of swelling. The radiographs are of the skull and teeth - performed under anesthesia.

RADIOGRAPHIC STUDY OF THE SKULL

Multiple radiographic projections of the skull are provided for review.

RADIOGRAPHIC FINDINGS

Multiple teeth are absent.

A moderate soft tissue swelling is seen in the region of the rostral aspect of the right zygomatic arch, extending rostrally along the right upper lip. The right zygomatic arch presents moderate sclerosis with loss of the trabecular pattern.

RADIOGRAPHIC DIAGNOSIS

- Soft tissue swelling region of rostral third of right zygomatic bone with sclerosis of the rostral segment of the zygomatic arch
- Multiple absent teeth

INTERPRETATION OF THE FINDINGS & FURTHER RECOMMENDATIONS

The swelling in combination with the osseous changes of the zygomatic arch are concerning for either neoplastic transformation (e.g. sarcoma, carcinoma) or chronic osteomyelitis. For further workup FNA sampling of the swelling and the zygomatic arch would be ideal.

If cytology results are inconclusive, a CT study of the skull might yield more diagnostic value.

REFERRING VET

Kevin Oran

INVOICE

54173

DATE

9-20-22



PATIENT

Chewy Duenas

SPECIES

Feline

BREED

Domestic Short Hair

SEX

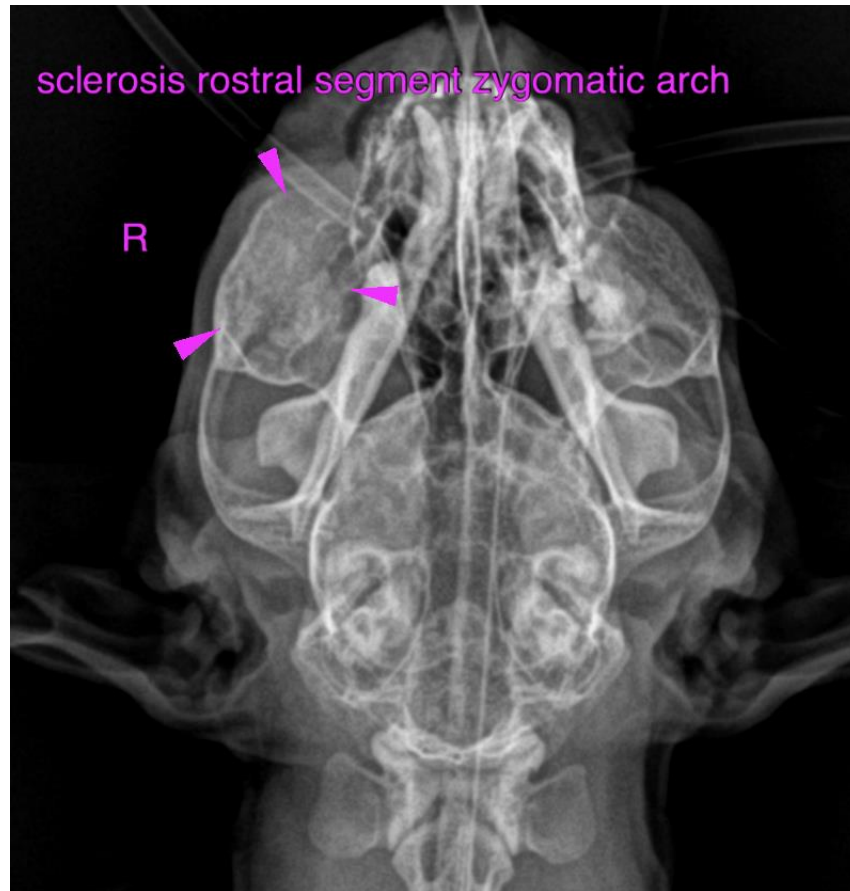
M

AGE

12

INTERPRETED BY

Sebastian Schaub, DVM
Dr. med. vet. DipECVDI



HOSPITAL NAME

Incline Veterinary
Hospital

REFERRING VET

Kevin Oran

INVOICE

54173

DATE

9-20-22

The information and recommendations provided are based on the images presented by the referring veterinarian/sonographer. No evaluation can be communicated regarding pathology that was not visible in the image/video clips provided.

Thank you for this referral. If the clinical or image interpretation does not parallel your findings or if I can be of any further assistance please contact me.

Sebastian Schaub, Sebastian Schaub, DVM, Dr. med. vet. DipECVDI
sebast.schaub@gmail.com