



PATIENT

Charlie Eimbinder

PRESENTING CLINICAL SIGNS

had acl surgery on right side stifle. has been limping on and off for the past 5 days . i do not detect a drawer sign on right side stifle but medical side of stifle joint is inflamed .

SPECIES

Canine

RADIOGRAPHIC STUDY OF THE STIFLE JOINTS

Radiographs of both stifle joints in two imaging planes are provided for review.

BREED

Goldendoodle

RADIOGRAPHIC FINDINGS

The volume of the right thigh musculature is moderately decreased.

The periarticular bones of the right stifle joint present mild osteophyte new bone formation. A horizontal drill-hole is appreciated caudal to the tuberositas tibiae within the proximal tibial metaphysis. Moderate caudal elongation of the right tibial plateau is noted. The right stifle joint presents a mild to moderate intracapsular soft tissue swelling.

SEX

Spayed Female

The left stifle joint presents smooth osseous margins and without signs of intracapsular swelling, unremarkable.

RADIOGRAPHIC DIAGNOSIS

AGE

8 Years

- History of cranial cruciate ligament surgery using an extracapsular suture technique with drill hole in the proximal right tibia
- Mild degenerative osteoarthritis right stifle joint
- Caudal elongation right tibial plateau
- Mild articular swelling right stifle joint
- Disuse atrophy right thigh musculature
- Normal left stifle joint.

INTERPRETED BY

Sebastian Schaub, DVM
Dr. med. vet. DipECVDI

INTERPRETATION OF THE FINDINGS & FURTHER RECOMMENDATIONS

A specific underlying cause for the relative acute onset of clinical signs is not appreciated. The osseous changes of the right stifle joint and the joint effusion are likely a sequela to preceding chronic instability. A synovial tap can be used to rule out infectious arthritis of the stifle joint and check if meniscal click is present, indicating accompanying meniscal injury. Implant failure might be a source for lameness as well.

HOSPITAL NAME

Tenafly Vet Center

REFERRING VET

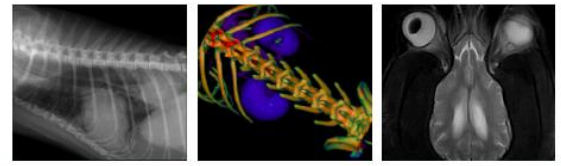
Kyoung Han

INVOICE

54143

DATE

9-20-22



PATIENT

Charlie Eimbinder

SPECIES

Canine

BREED

Goldendoodle

SEX

Spayed Female

AGE

8 Years

INTERPRETED BY

Sebastian Schaub, DVM
Dr. med. vet. DipECVDI

HOSPITAL NAME

Tenafly Vet Center

REFERRING VET

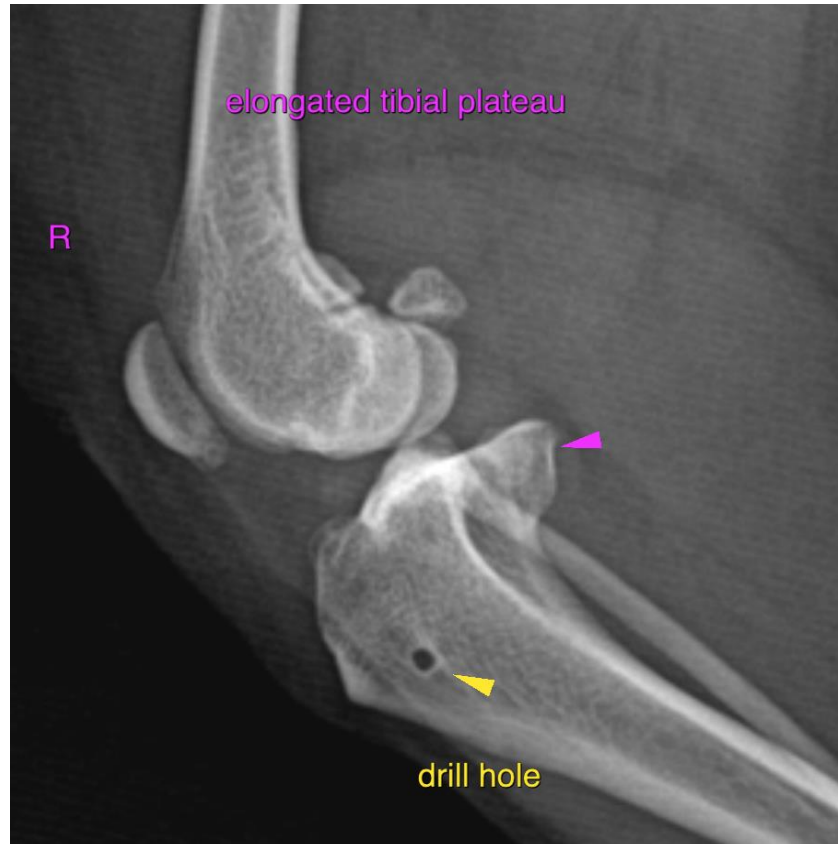
Kyoung Han

INVOICE

54143

DATE

9-20-22



The information and recommendations provided are based on the images presented by the referring veterinarian/sonographer. No evaluation can be communicated regarding pathology that was not visible in the image/video clips provided.

Thank you for this referral. If the clinical or image interpretation does not parallel your findings or if I can be of any further assistance please contact me.

Sebastian Schaub, Sebastian Schaub, DVM, Dr. med. vet. DipECVDI
sebast.schaub@gmail.com