



PATIENT

Busika Shkatula

SPECIES

Canine

BREED

Terrier Mix

SEX

Female Spayed

AGE

10 Years, 6 Months

INTERPRETED BY

Sebastian Schaub, DVM
Dr. med. vet. DipECVDI

HOSPITAL NAME

Mobile Pet Imaging

REFERRING VET

Meaux

INVOICE

47478

DATE

9-20-21

PRESENTING CLINICAL SIGNS

Presented Sept. 3rd for mass on the mammary area. The patient had a radical mastectomy a few years ago due to another mass. Intact female at this time. Radiographs showed ill define pulmonary nodule left cranial lung superimposed on the cardiac silhouette. Possible lipoma vs seroma ventral abdominal wall. Unremarkable abdomen.

Abnormal PE/Chem/CBC/UA Results: Scar along ventral abdomen, seroma vs lipoma ventral abdominal wall.

COMPUTED TOMOGRAPHY OF THE THORAX

A high resolution pre- and post-contrast CT study of the thorax is provided for review.

COMPUTED TOMOGRAPHIC FINDINGS

The thoracic spine presents with mild to moderate motion artefacts, no overt abnormalities of the osseous and surrounding soft tissue structures are appreciated.

The sternal, cranial mediastinal and tracheobronchial lymph nodes are small elongated with a normal short-to-long-axis-ratio is < 0.5, the attenuation and contrast enhancement pattern is uniform and considered within normal limits.

The cardiovascular structures including the pulmonary vasculature are within normal limits.

The bronchial tree presents with regular branching and tapers uniformly towards the periphery as expected, the bronchial walls are thin and smooth. The bronchus-to-artery ratio is within normal limits.

The lung parenchyma presents the expected architecture and attenuation behavior.

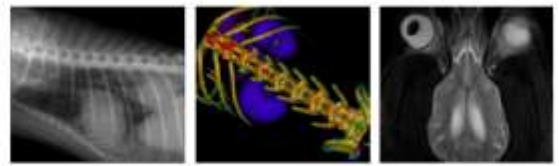
Small incidental gas pockets are seen within the esophageal lumen, there is no evidence of abnormal dilation.

COMPUTED TOMOGRAPHIC DIAGNOSIS

- Structural normal thorax, no evidence of pulmonary metastatic disease

INTERPRETATION OF THE FINDINGS & FURTHER RECOMMENDATIONS

The current CT study of the thorax is negative for pathology, there is no evidence of metastatic disease.



PATIENT

Busika Shkatula

The information and recommendations provided are based on the images presented by the referring veterinarian. No evaluation can be communicated regarding pathology that was not visible in the image/video clips provided.

SPECIES

Canine

Thank you for this referral. If the clinical or image interpretation does not parallel your findings or if I can be of any further assistance please contact me.

Sebastian Schaub, Sebastian Schaub, DVM, Dr. med. vet. DipECVDI
sebast.schaub@gmail.com

BREED

Terrier Mix

SEX

Female Spayed

AGE

10 Years, 6 Months

INTERPRETED BY

Sebastian Schaub, DVM
Dr. med. vet. DipECVDI

HOSPITAL NAME

Mobile Pet Imaging

REFERRING VET

Meaux

INVOICE

47478

DATE

9-20-21