



PATIENT PRESENTING CLINICAL SIGNS

Gunnarr Potthoff History: Aspiration pneumonia 6/1/22 and was hospitalized for a week and on simplicef for a week. Was doing well and came back for recheck xrays 6/17/22, then recheck xrays 7/7/22 and was doing well until it recurred 8/17/22 where we started him on meropenem. He did antibiotics for 2 weeks and a day and just stopped them today.

SPECIES

Canine

RADIOGRAPHIC STUDY OF THE THORAX

Radiographs of the thorax in three imaging planes are provided for review.

BREED

Weimeranar

RADIOGRAPHIC FINDINGS

In comparison to the previous radiographic studies, there is complete regression of the ventral alveolar pattern.

SEX

Neutered Male

RADIOGRAPHIC DIAGNOSIS

- Remission of the pneumonia

AGE

10 Years 10 Months

INTERPRETATION OF THE FINDINGS & FURTHER RECOMMENDATIONS

The current follow up radiographic study presents no signs for persistent pneumonia.

INTERPRETED BY

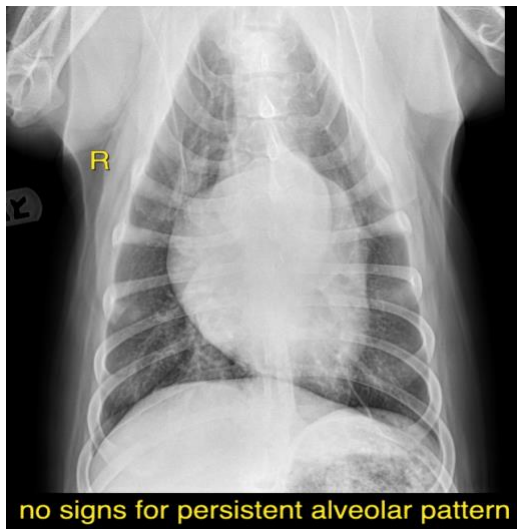
Sebastian Schaub,
DVM Dr. med. vet.
DipECVDI

HOSPITAL NAME

Elizabeth AH

REFERRING VET

Leon Anderson, DVM



INVOICE

17178

The information and recommendations provided are based on the images presented by the referring veterinarian/sonographer. No evaluation can be communicated regarding pathology that was not visible in the image/video clips provided.

DATE

9/2/22

Thank you for this referral. If the clinical or image interpretation does not parallel your findings or if



PATIENT I can be of any further assistance please contact me.

Gunnarr Potthoff

Sebastian Schaub, Sebastian Schaub, DVM, Dr. med. vet. DipECVDI
sebast.schaub@gmail.com

SPECIES

Canine

BREED

Weimeranar

SEX

Neutered Male

AGE

10 Years 10 Months

INTERPRETED BY

Sebastian Schaub,
DVM Dr. med. vet.
DipECVDI

HOSPITAL NAME

Elizabeth AH

REFERRING VET

Leon Anderson, DVM

INVOICE

17178

DATE

9/2/22