



PATIENT PRESENTING CLINICAL SIGNS

Bentley Abdelmalik History: Limping on the right hind Lack of appetite Vomited once On heart meds (furosemide + vetmedin) for +1yr

SPECIES Abnormal PE/Chem/CBC/UA Results: Upon PE... mild positive cranial drawer BW shows mild dehydration, severe pancreatitis, & hypokalemia

Canine

RADIOGRAPHIC STUDY OF THE STIFLE JOINTS

BREED A craniocaudal view of the stifle joints is provided for review.

Yorkshire Terrier

RADIOGRAPHIC FINDINGS

SEX

Both stifle joints present mild to moderate osteophyte new bone formation. The patella of both stifle joints is in situ. The right stifle joint presents a convex soft tissue swelling medially – ‘medial buttress’.

Neutered Male

RADIOGRAPHIC DIAGNOSIS

AGE

- Degenerative osteoarthritis stifle joints bilaterally
- Suspect articular swelling right stifle joint

10 Years

INTERPRETATION OF THE FINDINGS & FURTHER RECOMMENDATIONS

INTERPRETED BY

Sebastian Schaub,
DVM Dr. med. vet.
DipECVDI

The radiographic changes appreciated in the craniocaudal view indicate degenerative osteoarthritis of both stifle joints and potential joint effusion/synovial thickening of the right stifle joint. The most common underlying cause is pathology of the cranial cruciate ligament ± meniscal pathology. Check if a positive drawer sign or tibial compression test are appreciated, supporting the diagnosis.

HOSPITAL NAME

St. Catharine’s AH

REFERRING VET

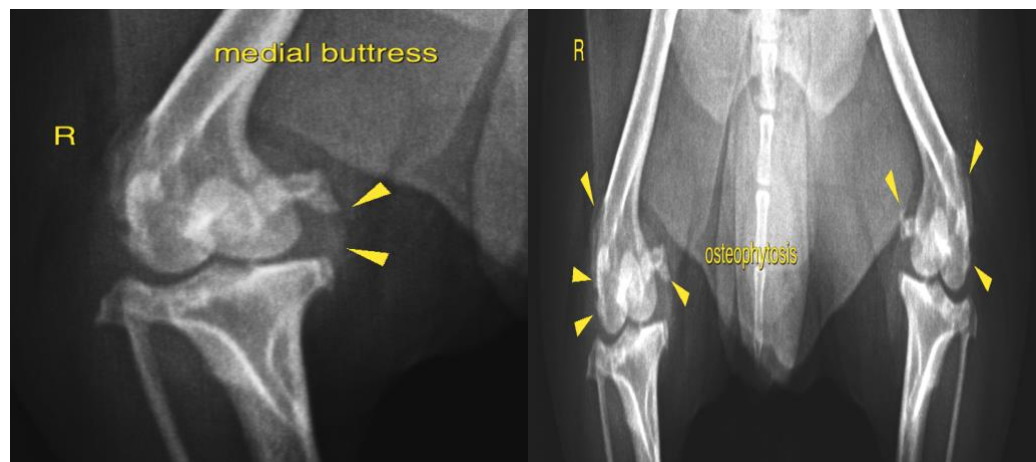
Dr. Masoud

INVOICE

17170

DATE

9/2/22





PATIENT

Bentley Abdelmalik

The information and recommendations provided are based on the images presented by the referring veterinarian/sonographer. No evaluation can be communicated regarding pathology that was not visible in the image/video clips provided.

SPECIES

Canine

Thank you for this referral. If the clinical or image interpretation does not parallel your findings or if I can be of any further assistance please contact me.

Sebastian Schaub, Sebastian Schaub, DVM, Dr. med. vet. DipECVDI
sebast.schaub@gmail.com

BREED

Yorkshire Terrier

SEX

Neutered Male

AGE

10 Years

INTERPRETED BY

Sebastian Schaub,
DVM Dr. med. vet.
DipECVDI

HOSPITAL NAME

St. Catharine's AH

REFERRING VET

Dr. Masoud

INVOICE

17170

DATE

9/2/22