



**PATIENT**

Willy Heillmann

**PRESENTING CLINICAL SIGNS**

Recent lameness after long walks, no injuries noticed. Reactive to shoulder flexion, no muscle wastage, no real improvement on anti inflammms, poss increased laxity in shoulder extension  
Abnormal PE/Chem/CBC/UA Results:

**SPECIES**

Canine

**COMPUTED TOMOGRAPHY OF THE SHOULDER JOINTS**

A plain CT study of the shoulder joints in a bone and soft tissue reconstruction is provided for review – including a positive contrast arthrography of the left shoulder joint.

**BREED**

Greyhound

**COMPUTED TOMOGRAPHIC FINDINGS**

Both shoulder joints present smooth osseous margins and the surrounding soft tissue structures are within normal limits.

**SEX**

Neutered Male

Post intrathecal contrast administration, a moderate amount of free gas is seen in the proximal outpouchings of the left shoulder joint. The bicipital tendon can be appreciated as smooth tubular filling defect within its synovial sheath formed by the joint capsule of the left shoulder joint, unremarkable. The surface of the joint cartilage along the humeral head and the glenoid fossa is smooth. The inner outline of the joint capsule of the right shoulder joint appears smooth.

**AGE**

5 Years, 11 Months

**COMPUTED TOMOGRAPHIC DIAGNOSIS**

- Normal right shoulder joint

**INTERPRETED BY**

Sebastian Schaub, DVM  
Dr. med. vet. DipECVDI

**INTERPRETATION OF THE FINDINGS & FURTHER RECOMMENDATIONS**

The CT study presents without abnormalities of both shoulder joints and the intraarticular structures of the left shoulder joint.

**HOSPITAL NAME**

Adelaide Plains  
Veterinary Surgery

Rule out lameness originating from the distal aspects of the respective front limb as well.

**REFERRING VET**

John Katakasi

**INVOICE**

54166

**DATE**

9-19-22



**PATIENT**

Willy Heillmann

**SPECIES**

Canine

**BREED**

Greyhound

**SEX**

Neutered Male

**AGE**

5 Years, 11 Months

**INTERPRETED BY**

Sebastian Schaub, DVM  
Dr. med. vet. DipECVDI

**HOSPITAL NAME**

Adelaide Plains  
Veterinary Surgery

**REFERRING VET**

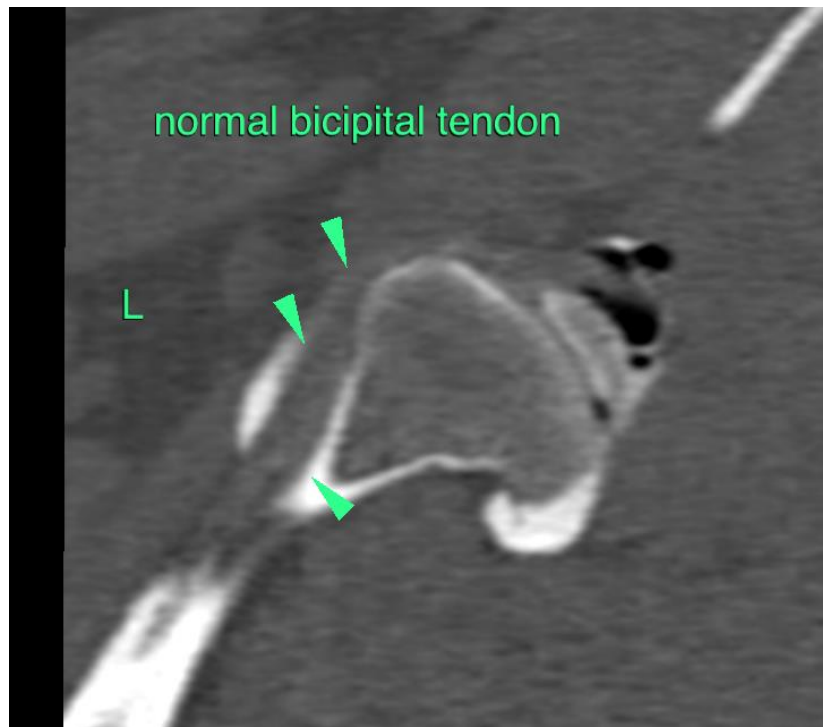
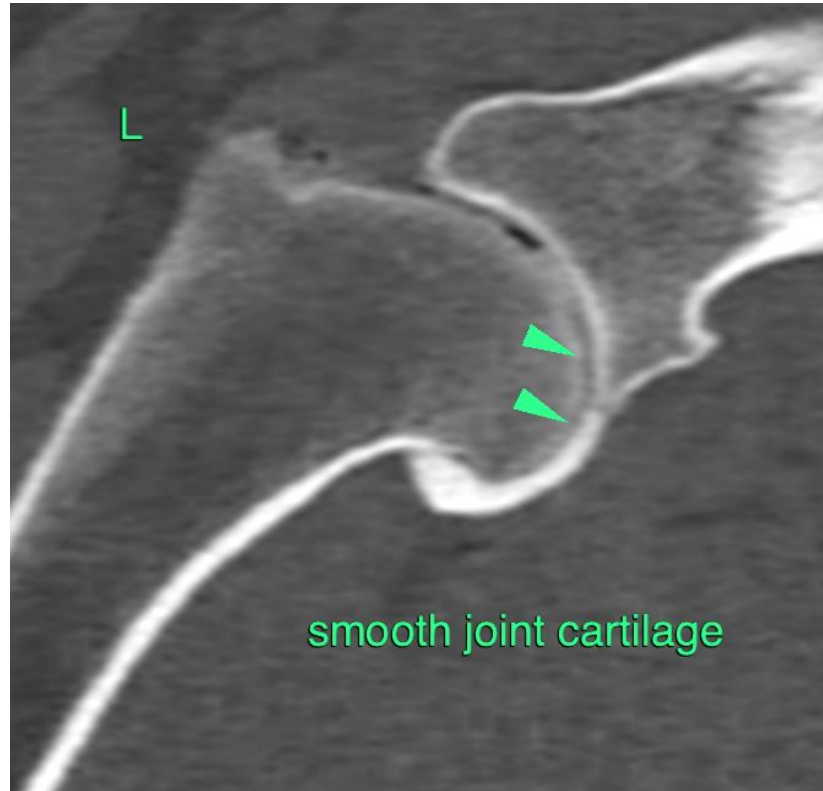
John Katakasi

**INVOICE**

54166

**DATE**

9-19-22





**PATIENT**

Willy Heillmann

**SPECIES**

Canine

The information and recommendations provided are based on the images presented by the referring veterinarian/sonographer. No evaluation can be communicated regarding pathology that was not visible in the image/video clips provided.

**BREED**

Greyhound

Thank you for this referral. If the clinical or image interpretation does not parallel your findings or if I can be of any further assistance please contact me.

**Sebastian Schaub**, Sebastian Schaub, DVM, Dr. med. vet. DipECVDI  
sebast.schaub@gmail.com

**SEX**

Neutered Male

**AGE**

5 Years, 11 Months

**INTERPRETED BY**

Sebastian Schaub, DVM  
Dr. med. vet. DipECVDI

**HOSPITAL NAME**

Adelaide Plains  
Veterinary Surgery

**REFERRING VET**

John Katakasi

**INVOICE**

54166

**DATE**

9-19-22