



**PATIENT**

Roxy Goodfellow

**PRESENTING CLINICAL SIGNS**

gingival mass over upper left fourth premolar noted at annual examination, owners unsure how long it had been there, biopsies pending  
Abnormal PE/Chem/CBC/UA Results:

**SPECIES**

Canine

**COMPUTED TOMOGRAPHY OF THE SKULL**

A high resolution pre- and post-contrast CT study of the viscerocranium is provided for review.

**BREED**

Border Collie

**COMPUTED TOMOGRAPHIC FINDINGS**

The pictured parts of the dentition are complete. At the buccal aspect of triadan 208 a fine granular mineralizing mass is appreciated, measuring 1.5 x 1.7 x 1.5 cm in size. The alveolar bone at the same level presents aggressive osteolysis and resorptive lesions of the associated roots of triadan 208 is noted.

**SEX**

Female Spayed

The nasal cavity presents the expected aerated spaces between thin & even conchae and turbinates with smooth mucosal lining.

**COMPUTED TOMOGRAPHIC DIAGNOSIS**

- Monostotic semiaggressive osteoproliferative mass buccal aspect left maxillary bone level 208

**AGE**

8 Years

**INTERPRETATION OF THE FINDINGS & FURTHER RECOMMENDATIONS**

Given the location of the mass and its association with the roots of triadan 208 the odds for odontogenic tumor are high (e.g. cemento-ossifying or cementifying fibroma). A potential is primary tumor of the left maxillary bone – such as chondrosarcoma, osteochondrosarcoma, osteosarcoma. Biopsy of the mass has already been performed, regarding the history and results are pending. Depending on biopsy results, the chances of segmental maxillectomy or radiation therapy can be discussed with surgeon/oncologist.

**INTERPRETED BY**

Sebastian Schaub, DVM  
Dr. med. vet. DipECVDI

Consider full tumor staging.

**HOSPITAL NAME**

Petroglyph Animal  
Hospital

**REFERRING VET**

Dr. Dana Powers

**INVOICE**

54118

**DATE**

9-19-22



**PATIENT**

Roxy Goodfellow

**SPECIES**

Canine

**BREED**

Border Collie

**SEX**

Female Spayed

**AGE**

8 Years

**INTERPRETED BY**

Sebastian Schaub, DVM  
Dr. med. vet. DipECVDI

**HOSPITAL NAME**

Petroglyph Animal  
Hospital

**REFERRING VET**

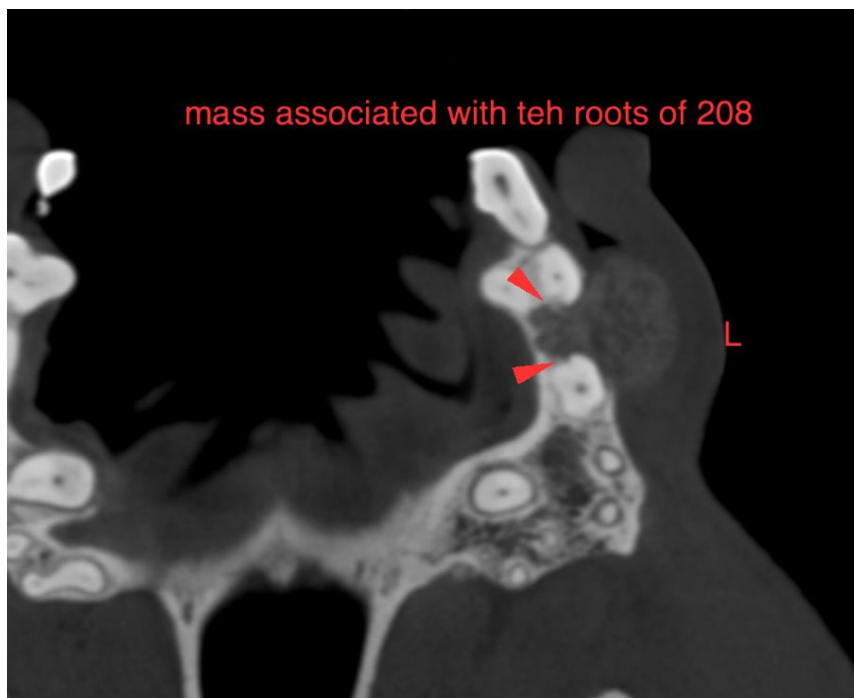
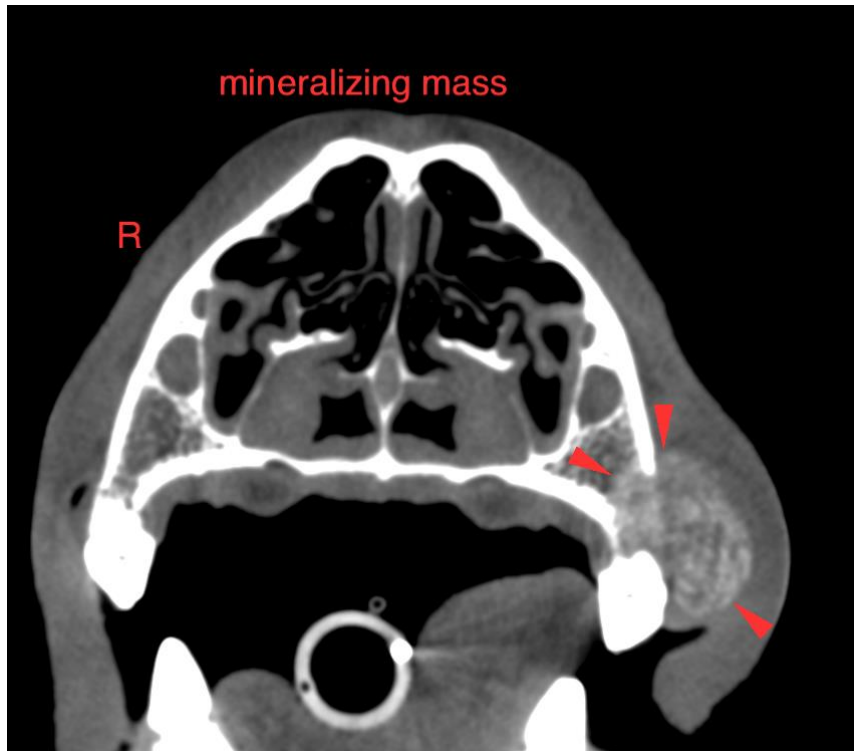
Dr. Dana Powers

**INVOICE**

54118

**DATE**

9-19-22





**PATIENT**

Roxy Goodfellow

**SPECIES**

Canine

**BREED**

Border Collie

**SEX**

Female Spayed

**AGE**

8 Years

**INTERPRETED BY**

Sebastian Schaub, DVM  
Dr. med. vet. DipECVDI

**HOSPITAL NAME**

Petroglyph Animal  
Hospital

**REFERRING VET**

Dr. Dana Powers

**INVOICE**

54118

**DATE**

9-19-22

The information and recommendations provided are based on the images presented by the referring veterinarian/sonographer. No evaluation can be communicated regarding pathology that was not visible in the image/video clips provided.

Thank you for this referral. If the clinical or image interpretation does not parallel your findings or if I can be of any further assistance please contact me.

**Sebastian Schaub**, Sebastian Schaub, DVM, Dr. med. vet. DipECVDI  
sebast.schaub@gmail.com