

**PATIENT**

Lily Crowley

PRESENTING CLINICAL SIGNS

NON-WEIGHT BEARING ON LEFT FRONT , SEVER PAIN RESPONSE WHEN PRESSURE IS APPLIED ON LEFT ELBOW , ELBOW IS MILDLY SWOLEN , AS WELL
Abnormal PE/Chem/CBC/UA Results: CBC shows Neutrophilia, lymphocytopenia, and low monocyte percent chemistry shows hypokalemia, other unremarkable

SPECIES

Canine

RADIOGRAPHIC STUDY OF THE ELBOW JOINTS

Radiographs of the elbow joints in orthogonal imaging planes are provided for review.

BREED

German Shepherd

RADIOGRAPHIC FINDINGS

The periarticular bones of both elbow joints present advanced osteophyte new bone formation. The anconeal process bilaterally is isolated from the olecranon and the osseous margins are smooth with moderate sclerosis. The contour of the medial coronoid process of both elbow joints is ill-defined.

SEX

Female Spayed

In the craniocaudal view, the elbow joints are superimposing with anatomy of the skull.

RADIOGRAPHIC DIAGNOSIS

- Coronoid disease elbow joints bilaterally
- Ununited anconeal process (UAP) elbow joints bilaterally
- Advanced degenerative osteoarthritis elbow joints bilaterally

AGE

9 Years

INTERPRETED BY

Sebastian Schaub, DVM
Dr. med. vet. DipECVDI

INTERPRETATION OF THE FINDINGS & FURTHER RECOMMENDATIONS

The radiographic study of the elbow joints is consistent with advanced degenerative osteoarthritis of the elbow joint, secondary to coronoid disease and ununited anconeal process. Acute on chronic insult may have caused acute deterioration of clinical signs. However, if there are clinical signs of joint effusion arthritis needs to be ruled out by a synovial tap.

HOSPITAL NAME

St. Catherine's Animal
Hospital

REFERRING VET

Dr. Boctor

INVOICE

54105

DATE

9-19-22



PATIENT

Lily Crowley

SPECIES

Canine

BREED

German Shepherd

SEX

Female Spayed

AGE

9 Years

INTERPRETED BY

Sebastian Schaub, DVM
Dr. med. vet. DipECVDI

HOSPITAL NAME

St. Catherine's Animal
Hospital

REFERRING VET

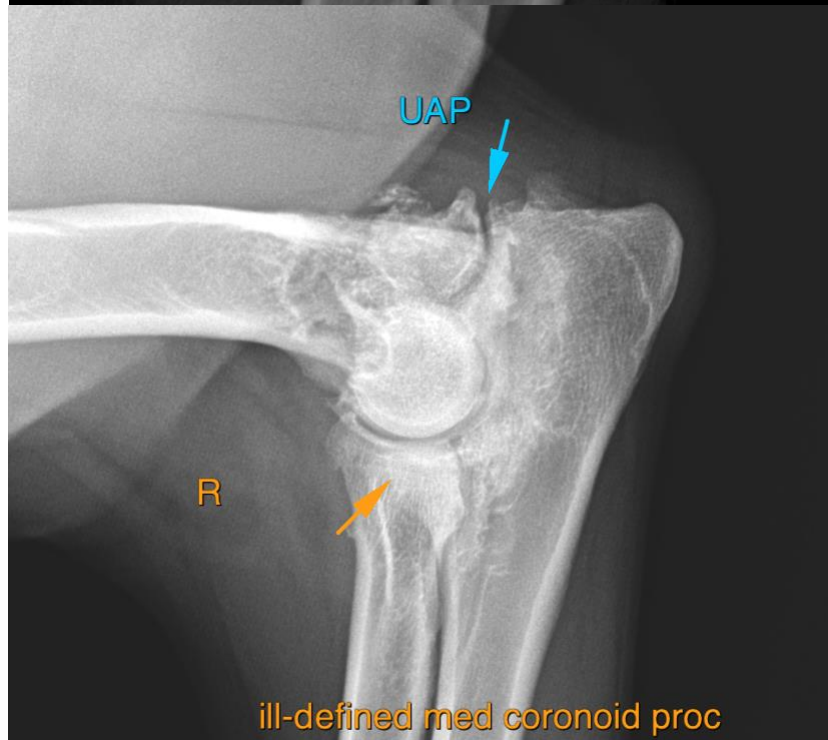
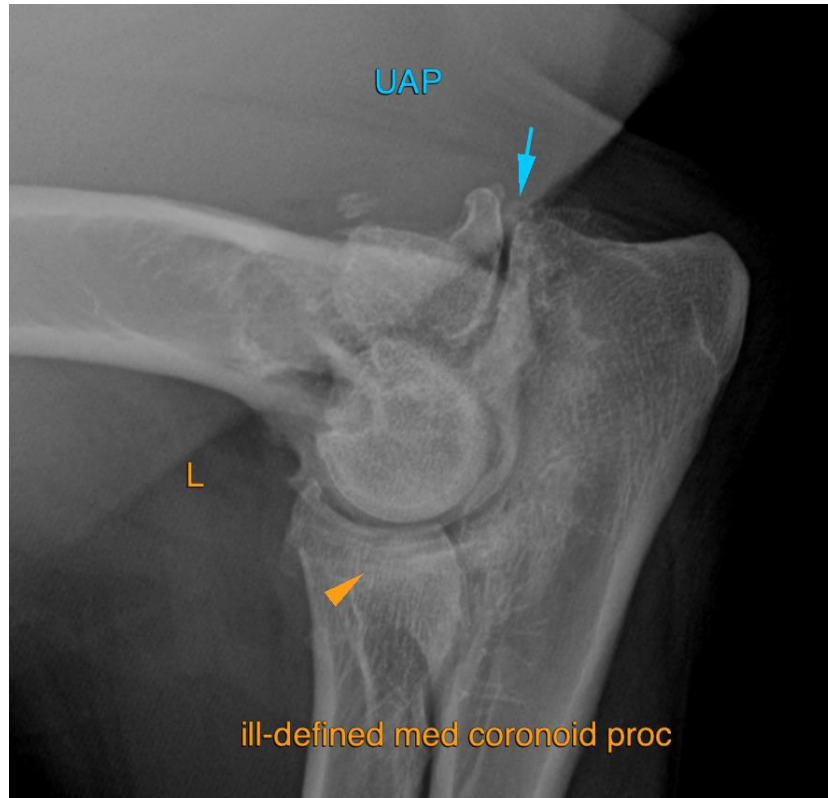
Dr. Boctor

INVOICE

54105

DATE

9-19-22





PATIENT

Lily Crowley

SPECIES

Canine

The information and recommendations provided are based on the images presented by the referring veterinarian/sonographer. No evaluation can be communicated regarding pathology that was not visible in the image/video clips provided.

BREED

German Shepherd

Thank you for this referral. If the clinical or image interpretation does not parallel your findings or if I can be of any further assistance please contact me.

Sebastian Schaub, Sebastian Schaub, DVM, Dr. med. vet. DipECVDI
sebast.schaub@gmail.com

SEX

Female Spayed

AGE

9 Years

INTERPRETED BY

Sebastian Schaub, DVM
Dr. med. vet. DipECVDI

HOSPITAL NAME

St. Catherine's Animal
Hospital

REFERRING VET

Dr. Boctor

INVOICE

54105

DATE

9-19-22