

**PATIENT**

Jackson Quintiliano

**PRESENTING CLINICAL SIGNS**

P limping on/off on left front. Improves after moving around.  
Abnormal PE/Chem/CBC/UA Results: No pain on palpation. Overweight.

**SPECIES**

Canine

**RADIOGRAPHIC STUDY OF THE CERVICAL SPINE AND SHOULDER JOINTS**

Radiographs of the shoulder joints and the cervical spine in two imaging planes are provided for review.

**BREED**

King Charles Spaniel

**RADIOGRAPHIC FINDINGS**

The lateral projection of the cervical spine is moderately rotated, no abnormalities of the osseous and surrounding soft tissue structures are appreciated. The intervertebral disc spaces of the cervical spine are of even width in the VD view.

**SEX**

NM

The shoulder joints are superimposing with the manubrium sterni in the mediolateral views. The osseous margins of the shoulder joints bilaterally are smooth. Proximal to the greater tubercle of the left humerus, a small (<2 mm) mineral opaque body is appreciated.

**AGE**

7 Years

**RADIOGRAPHIC DIAGNOSIS**

- Small mineral opaque body proximal to major tubercle left humerus
- Normal cervical spine

**INTERPRETED BY**

Sebastian Schaub, DVM  
Dr. med. vet. DipECVDI

**INTERPRETATION OF THE FINDINGS & FURTHER RECOMMENDATIONS**

The radiographic study of the cervical spine and the shoulder joints presents without specific abnormalities, explaining the front limb lameness.

The mineral opaque body appreciated proximal to the left major tubercle of the left humerus can be caused by superimposition of dystrophic mineralization, calcifying tendinopathy of the supraspinatus muscle (questionable clinical relevance), mineralized body attached to fur.

**HOSPITAL NAME**

The Pet Hospital of  
Stratford

In case of strong clinical suspicion for pathology of the bicipital tendon or rotator cuff injury, recommend complementing workup by an ultrasound examination of the shoulder joint.

**REFERRING VET**

Dr. Giuliani

**INVOICE**

54120

**DATE**

9-19-22



**PATIENT**

Jackson Quintiliano

**SPECIES**

Canine

**BREED**

King Charles Spaniel

**SEX**

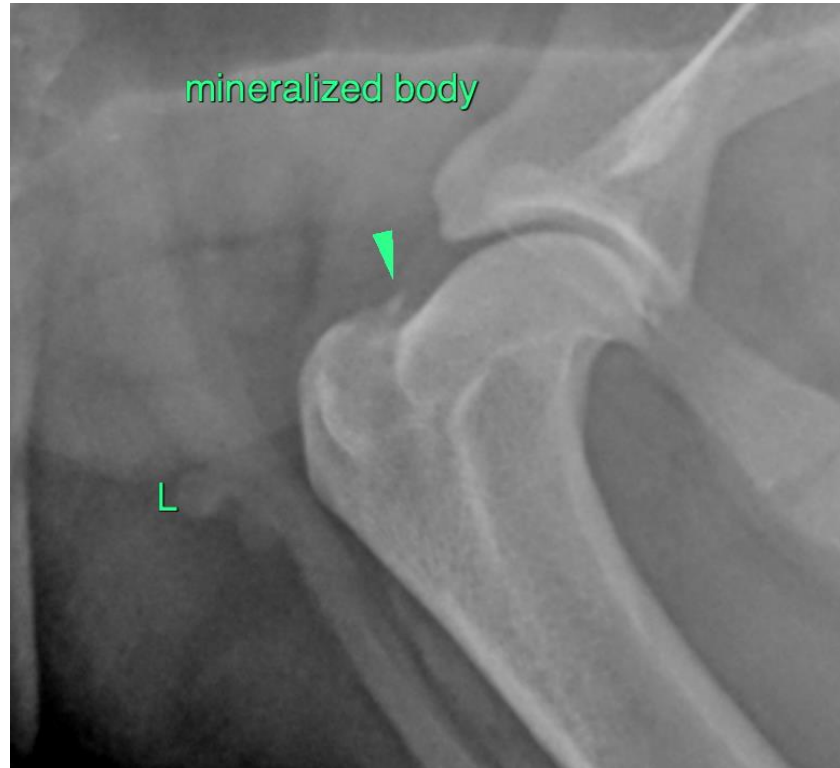
NM

**AGE**

7 Years

**INTERPRETED BY**

Sebastian Schaub, DVM  
Dr. med. vet. DipECVDI



**HOSPITAL NAME**

The Pet Hospital of  
Stratford

**REFERRING VET**

Dr. Giuliani

**INVOICE**

54120

**DATE**

9-19-22

The information and recommendations provided are based on the images presented by the referring veterinarian/sonographer. No evaluation can be communicated regarding pathology that was not visible in the image/video clips provided.

Thank you for this referral. If the clinical or image interpretation does not parallel your findings or if I can be of any further assistance please contact me.

**Sebastian Schaub**, Sebastian Schaub, DVM, Dr. med. vet. DipECVDI  
sebast.schaub@gmail.com